Original Research Article

Conservative versus open reduction internal fixation (ORIF) for pediatric supracondylar humerus fractures gartland type II and III: a systematic review and meta-analysis

Putu Astawa[1]

[1]Department of Orthopaedics and Traumatology, Faculty of Medicine, Universitas Udayana

ABSTRACT

Introduction: Displaced supracondylar humerus fracture in children presents a challenge for surgeons, as the treatment of choice is still controversial, considering the functional and cosmetic outcomes as well as the surgical risks it might carry. This study aims to compare the outcomes of two kinds of treatments for the pathology: Conservative versus Open Reduction with Internal Fixation (ORIF).

Methods: A systematic review using PubMed and Google Scholar was conducted based on PRISMA guideline. Inclusion criteria were studies with samples aged <18 years old, comparing conservative and ORIF procedure for Supracondylar Humerus Fractures Gartland Type II and III, with Flynn criteria as the main outcome. Studies of only one surgical technique modality, Gartland type I, and case reports were excluded. For the meta-analysis, a total of 3 studies were included and fixed effect model was used to pool the result. In each study, mean difference (MD) with a 95% confidence interval (CI) was calculated for dichotomous outcomes using Review Manager 5.3.

Results: Fifty-one patients aged 1-14.6 years old were included in the analysis. Male and female were equally affected, and conservative procedure was done more often than ORIF. Based on Flynn's Criteria, satisfactory outcomes (excellent or good) were achieved in 58.62% of patients in the conservative and 86.36% in the ORIF group, indicating a significant difference (Heterogeneity, I^2 = 20%; WMD, 0.23; 0.06 to 0.91; P=0.04).

Conclusion: Current systematic review and meta-analysis suggest that ORIF offers superior functional and cosmetic outcomes compared to conservative methods for pediatric displaced supracondylar humerus fracture.

Keywords: conservative, open reduction internal fixation, supracondylar humerus fracture.
https://doi.org/10.31282/joti.v4n1.71

Corresponding author : Prof. Putu Astawa, MD. Email : prof.putuastawaspot@gmail.com

INTRODUCTION

Supracondylar humerus fracture is a fracture involving the thin portion of humerus through coronoid or olecranon fossa, just above the fossa, or through the metaphysis of the humerus. It accounts for 60% of all elbow fractures and represents approximately 3% of all fractures in pediatric population, especially those aged 5-7 years old.[1] As a metaphyseal injury, supracondylar humerus fracture is almost exclusively seen in the immature skeleton, rarely found in children older than ten years old. Ligamentous laxity commonly found in the growing skeleton is also associated with hyperextension of the elbow, focusing a bending force on the susceptible supracondylar area. In these cases, the achievement of accurate anatomical reduction in the coronal plane plays an important role, as residual deformity in this region is less likely to remodel.[2]

Undisplaced supracondylar humerus fracture usually requires only simple immobilization for comfort and protection. On the other hand, displaced supracondylar humerus fracture in children presents a challenge for surgeons, as the treatment of choice is still controversial, considering the functional and cosmetic outcomes as well as the surgical risks it might carry. Some of the most common surgical procedures performed for this condition are Open Reduction Internal Fixation (ORIF) and Closed Reduction with Percutaneous Pinning (CRPP). Whereas some of the most common conservative treatment options are closed reduction and cast immobilization, traction, and collar and cuff.[1,3]

In the cases of displaced supracondylar humerus fractures, conservative methods have traditionally been recommended, but loss of reduction is often found, leading to the necessity for repeated manipulation to correct malunion, varus or valgus deformity as well as stiffness. Furthermore, surgical treatment is generally reserved for more complicated cases or if conservative methods fail. For the last few years, there is a trend towards operative fixation in displaced fractures, however there is no consensus of opinion regarding the most effective treatment.[2] Given the scarcity of studies for an optimal management for such injuries, this systematic review and meta-analysis aims to compare the outcomes of two kinds of treatments for the pathology: Conservative versus Open Reduction with Internal Fixation (ORIF).

MATERIALS AND METHODS

Table 1. PICO Table Describing Inclusion and Exclusion Criteria

Study Component	Inclusion	Exclusion
Population	• Aged <18 years old • Patients with supracondylar humerus fracture Gartland type II and III	• Animal studies • Aged ³18 years old • Patients with supracondylar humerus fracture Gartland type I or other kinds of fractures
Intervention	• ORIF • Conservative treatment	• Other methods of treatment • Studies with only one method of treatment
Outcome	Flynn's criteria, other outcome parameters, complications	No outcome mentioned or different outcomes
Publication	• Studies published in English in peer-reviewed journals • Any publication year	• Abstracts, editorials, letters • Duplicate publications of the same study that do not report on different outcomes • Meeting presentations or proceedings
Study Design	All study design except case reports and review articles	Case reports, review articles

A systematic review using PubMed and Google Scholar was conducted based on PRISMA guideline to identify relevant articles, which were searched up through June 2019 using the keywords "conservative" AND "Open Reduction Internal Fixation" AND "supracondylar humerus fracture". Those data were then manually scanned and reviewed by all authors. Inclusion criteria were studies with samples aged <18 years old, comparing

conservative and ORIF procedure for Supracondylar Humerus Fractures Gartland Type II and III, with Flynn criteria as the main outcome. Studies of only one surgical technique modality, Gartland type I, and case reports were excluded. Studies with samples older than 18 years old were excluded from the analysis, considering that World Health Organization (WHO) criteria for pediatric population comprises individuals below 18 years old. Gartland type I fracture was excluded because of minimal degree of displacement, and case reports were excluded because the sample size is insignificant to draw conclusion from.

For the meta-analysis, a total of 3 studies were included and fixed effect model was used to pool the result. The quality of the three articles was evaluated using The Joanna Briggs Institute (JBI) Critical Appraisal Tools. The results are shown in Table 2. All three studies provided clear research purposes, coherent patients, objective results, clear methods of data collection, and adequate follow-up time. One study stated unclear confounding factors and strategies to deal with those factors. On the other hand, another study did not recruit homogenous population. Eventually, three studies with a JBI score of more than 8 were included in this meta-analysis.

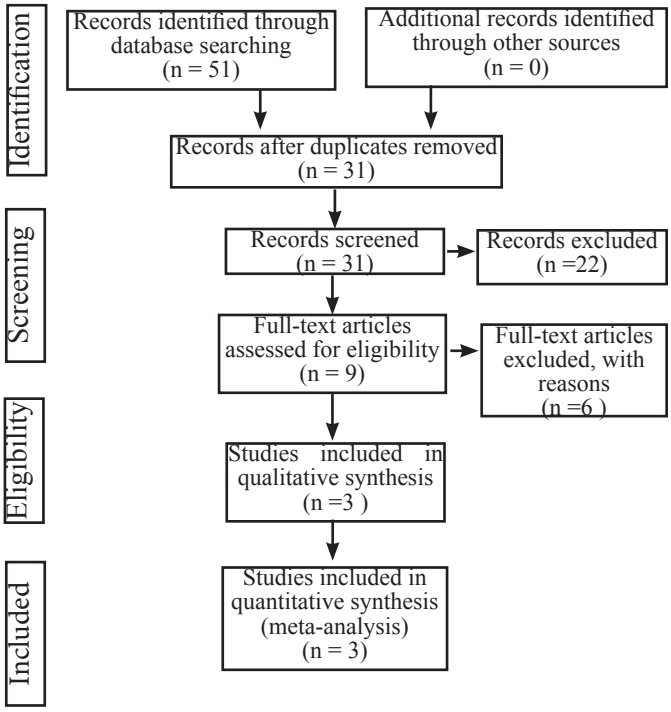

Figure. 1. Flow chart showing article selection based on PRISMA guideline

The data extraction was collected under basic characteristics and outcomes, mainly Flynn criteria. In each study, mean difference (MD) with a 95% confidence interval (CI) was calculated for dichotomous outcomes using Review Manager 5.3.

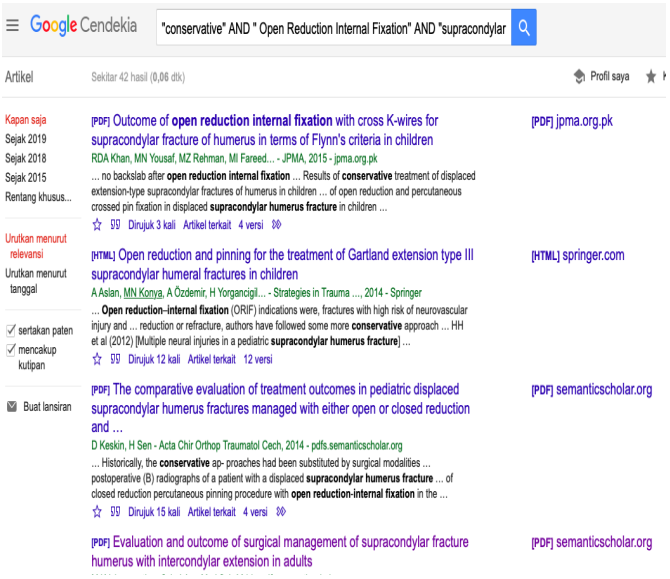

Figure 2. Boolean operator search result

	Yes	No	Unclear	Not applicable
1. Were the two groups similar and recruited from the same population?	☐	☐	☐	☐
2. Were the exposures measured similarly to assign people to both exposed and unexposed groups?	☐	☐	☐	☐
3. Was the exposure measured in a valid and reliable way?	☐	☐	☐	☐
4. Were confounding factors identified?	☐	☐	☐	☐
5. Were strategies to deal with confounding factors stated?	☐	☐	☐	☐
6. Were the groups/participants free of the outcome at the start of the study (or at the moment of exposure)?	☐	☐	☐	☐
7. Were the outcomes measured in a valid and reliable way?	☐	☐	☐	☐
8. Was the follow up time reported and sufficient to be long enough for outcomes to occur?	☐	☐	☐	☐
9. Was follow up complete, and if not, were the reasons to loss to follow up described and explored?	☐	☐	☐	☐
10. Were strategies to address incomplete follow up utilized?	☐	☐	☐	☐
11. Was appropriate statistical analysis used?	☐	☐	☐	☐

Overall appraisal: Include ☐ Exclude ☐ Seek further info ☐

Figure 3. JBI Critical Appraisal Tools Form for Cohort Studies

RESULTS

Fifty-one patients aged 1-14.6 years old were included in the analysis. Study designs were all cohort prospective (Level II-III). Two studies were done in 2016 and one in 2017. Male and female were equally affected, and

Table 2. JBI Critical Appraisal Tools Result

Study	1	2	3	4	5	6	7	8	9	10	11	Total
Sinikumpu, 2016 [2]	Yes	Yes	Yes	Unclear	Unclear	Yes	Yes	Yes	Yes	Yes	Yes	**9**
Joshi, 2016 [3]	No	Yes	Yes	Yes	Yes	Yes	Yes	Yes	Yes	Unclear	Yes	**9**
Sachin, 2017 [1]	Yes	Yes	Yes	Yes	Yes	Yes	Yes	Yes	Yes	Yes	Yes	**11**

conservative procedure was done more often than ORIF. From 51 patients, 29 patients were treated conservatively and 22 operatively by ORIF. From 29 conservatively-treated patients, most were Gartland type II (58.62%). Whereas in the ORIF group, most were Gartland type III (90.9%). Conservative treatments includes cast, splint, and closed reduction followed by collar and cuff. Operative treatment includes Open Reduction Internal Fixation, with plate-screw and intramedullary pinning as fixation modality.

Patients were assessed functionally using Flynn's criteria. Flynn's criteria include two factors, 'cosmetic factor' (loss of carrying angle) and 'functional factor' (motion loss in degrees). In this study, the Flynn's criteria were grouped into satisfactory and unsatisfactory results. Excellent and good results are considered satisfactory, while fair and poor results are considered unsatisfactory. Considering the low heterogeneity of the studies involved, fixed effect model was used for the analysis. Based on Flynn's Criteria, satisfactory outcomes were achieved in 58.62% of patients in conservative and 86.36% in ORIF group, indicating a significant difference (Heterogeneity, I^2 = 20%; WMD, 0.23; 0.06 to 0.91; P=0.04). One study mentioned Mayo Elbow Performance Scores as an outcome parameter, stating that both procedures had equally excellent outcome score (96.4 ±8.2). In terms of hospital length of stay, conservative group is superior compared to operative group, where the average hospital length of stay was 2 days for conservative and 12 days in operative group. Some complications mentioned are Vascular Injury (2.5%), Radial Nerve Injury (2.5%), Elbow Stiffness (5%), Cubitus Varus (7.5%), Cubitus Valgus (2.5%), Superficial Pin Tract Infection (2.5%). The average follow-up time in all literatures were 8.6-145.2 months.

DISCUSSION

As one of the most common traumatic pathologies in children, fractures around the elbow constitute one in three pediatric fractures. Supracondylar humerus fracture itself is almost exclusively seen in the immature skeleton, mostly in children under ten years. Anatomically, the narrow supracondylar region is in a higher risk of fracture due to the presence of the olecranon fossa posteriorly and the coronoid fossa anteriorly. Furthermore, ligamentous laxity with hyperextension of the elbow is common in the growing skeleton, focusing a bending force on the susceptible supracondylar area.[2] Though there has been a general agreement that undisplaced supracondylar fracture is better treated conservatively, the treatment for displaced fractures is still being debated.[4]

Displaced supracondylar fractures include Gartland type II and III fractures. Gartland type II fracture is displaced (by >2 mm), and the posterior cortex is presumably intact, but hinged. While Gartland type III fracture is a displaced supracondylar fracture with no meaningful cortical contact. Furthermore, in Gartland type III fracture, there is a translational and a rotational displacement which can explain the greater lateral rotational percentage.[5] In displaced supracondylar humerus fractures, soft tissue compromise resulting from severe trauma might prevent accurate reduction and steady fixation using closed methods. Besides, unstable fracture anatomy and short lever arm may also increase the risk for loss of reduction.[6] As one of the conservative methods, closed reduction with plaster of Paris slab immobilization has traditionally been recommended for displaced supracondylar fractures, but loss of reduction and necessity of repeated manipulation is likely to go for malunion producing varus or valgus elbow and elbow stiffness.[7] On the other hand, immobilization with plaster cast/moulded gutter-shape slab in extension has also been described, though it also resulted in cubitus varus in flexion type fractures.[8]

Although the management of supracondylar fractures of the humerus in children should focus on achieving fracture union and gaining painless full range of motion

at the end of the treatment, conservative methods may still be considered for low-demanding patients and patients for whom surgery can't be considered due to severe comorbidities.[9,10] However, in active patients who are eligible for surgery, and when conservative treatment fails to meet satisfaction, surgical treatment is

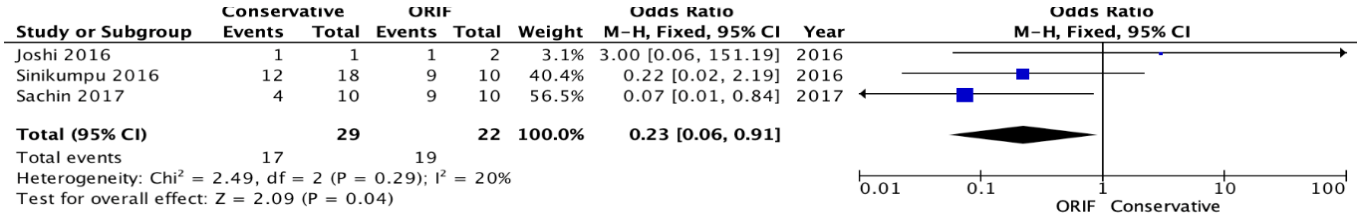

Figure 4. Analysis of Flynn's criteria between Conservative and ORIF

Table 3. Study Design and Level of Evidence from each study

No.	Reference	Journal	Study Design	Level of Evidence
1.	Sinikumpu, 2016 [2]	The Bone and Joint Journal	Cohort Retrospective	Level III
2.	Joshi, 2016 [3]	Journal of Lumbini Medical College	Cohort Retrospective	Level III
3.	Sachin, 2017 [1]	International Journal of Orthopaedics Sciences	Cohort Prospective	Level II

Table 4. Patient characteristics and Procedure of treatment

No.	Reference	Patient Characteristics						Procedure	
		Sample Size	Age (years)	Sex		Grade			
				Male	Female	Conservative	ORIF	Conservative	ORIF
1.	Sinikumpu 2016 [2]	28	6.3 (1.2 -14.6)	12 (43%)	16 (57%)	• Gartland type II: 17 (60.71%) • Gartland type III: 1 (3.57%)	• Gartland type II: 2 (7.14%) • Gartland type III: 8 (28.57%)	Splinting: 18 (64.29%)	10 (35.71%)
2.	Joshi, 2016 [3]	3	9.5±2.1 (6-14)	2 (66.7%)	1 (33.3%)	Gartland Type III	Gartland type III	MUA Cast: 1 (100%)	• Mini open Intramedullary pinning: 1 (50%) • Debridement + ORIF: 1 (50%)
3.	Sachin, 2017 [1]	20	1 - 14	12 (60%)	8 (40%)	Gartland type III: 10 (50%)	Gartland type III: 10 (50%)	Closed reduction + Splint + Collar and Cuff: 10 (50%)	10 (50%)

inevitable.[11] Therefore, despite the surgical risks they may carry, operative procedures such as ORIF should still be considered as the treatment of choice for the pathology. Though more invasive, ORIF is proved to result in higher satisfaction rate in terms of functional and cosmetic outcomes, compared to conservative methods such as splinting, casting, and collar-cuff. However, some complications should be monitored closely perioperatively, such as the risk of infection and neurovascular injuries. Accurate perioperative imaging and proper knowledge of surrounding anatomy are beneficial in achieving maximum outcome.[1] In evaluating the outcome of treatment, Flynn's criteria, as used in our meta-analysis, is a widely accepted method comprising functional elements such as range of motion, and cosmetic elements such as the change in carrying angle. The Baumann angle after reduction, measured on plain radiograph between the long axis of the humerus and the growth plate of the capitellum, can accurately predict the final carrying angle.[12]

There were several limitations in this meta-analysis: (1) only 3 potential studies were included, therefore the effect size was relatively small; (2) the management of

Table 5. Outcomes and Complications

No.	Reference	Outcome						Complications		Follow Up Time (Month)
		Functional (Flynn)		Hospital Stay (Days)		Other Outcome				
		Conservative	ORIF	Conservative	ORIF	Conservative	ORIF	Conservative	ORIF	
1.	Sinikumpu, 2016 [2]	Satisfactory: 12 (66.67%)	Satisfactory: 9 (90%)	N/A	N/A	Mayo Elbow Performance Scores 96,4 ± 8,2		N/A	N/A	145.2 (123.6 – 193.2)
2.	Joshi, 2016 [3]	Good: 1 (100%)	• Good: 1 (50%) • Fair: 1 (50%)	N/A	N/A	N/A	N/A	N/A	N/A	12.9 ±3.9
3	Sachin, 2017 [1]	• Excellent: 3 (30%) • Good: 1 (10%)	• Excellent: 6 (60%) • Good: 3 (30%)	2 days	12 days	N/A	N/A	• Vascular Injury: 1 (2.5%) • Radial Nerve Injury: 1 (2.5%) • Elbow Stiffness: 2 (5%) • Cubitus Varus: 3 (7.5%) • Cubitus Valgus: 1 (2.5%) • Superficial Pin Tract Infection: 1 (2.5%)		8.6

the conservative treatment was different from one study to another, and thus may contribute to the heterogeneity of the outcomes; (3) subgroup analysis was not performed since the number of the included studies were limited and more RCTs are needed to further accurately identify the clinical outcomes of these two managements.

CONCLUSION

Current systematic review and meta-analysis suggests that ORIF offers superior functional and cosmetic outcomes compared to conservative methods for pediatric displaced supracondylar humerus fracture.

Declarations

Funding: No Founding sources
Conflict of interest: None declared
Ethical approval: The Study was Approved by the Institutional Ethics Committee

REFERENCES

1. Sachin D. Management of supracondylar fractures of the humerus in children: Conservative versus operative. Int J Orthop Sci. Epub ahead of print 2017. DOI: 10.22271/ortho.2017.v3.i1a.04.
2. Sinikumpu JJ, Victorzon S, Pokka T, et al. The long-term outcome of childhood supracondylar humeral fractures: A population-based follow up study with a minimum follow up of ten years and normal matched comparisons. Bone Jt J 2016; 98-B: 1410–1417.
3. Joshi RR, Dwivedi R, Byanjankar S, et al. Simultaneous Ipsilateral Pediatric Fractures of the Elbow and Forearm Attending a Tertiary Care Hospital. J Lumbini Med Coll. Epub ahead of print 2016. DOI: 10.22502/jlmc.v4i1.85.
4. de Gheldere A, Bellan D. Outcome of gartland type II and type III supracondylar fractures treated by blount′s technique. Indian J Orthop. Epub ahead of print 2009. DOI: 10.4103/0019-5413.58612.
5. Omid R, Choi PD, Skaggs DL. Supracondylar humeral fractures in children. Journal of Bone and Joint Surgery - Series A. Epub ahead of print 2008. DOI: 10.2106/JBJS.G.01354.
6. Zorrilla S. de Neira J, Prada-Cañizares A, Marti-Ciruelos R, et al. Supracondylar humeral fractures in children: current concepts for management and prognosis. International Orthopaedics. Epub ahead of print 2015.

DOI: 10.1007/s00264-015-2975-4.
7. Bernasek TL. Campbell's operative orthopaedics. Journal of Orthopaedic Trauma. Epub ahead of print 1989. DOI: 10.1097/00005131-198912000-00021.
8. Chen RS, Liu CB, Lin XS, et al. Supracondylar extension fracture of the humerus in children. Manipulative reduction, immobilisation and fixation using a U-shaped plaster slab with the elbow in full extension. J Bone Joint Surg Br. Epub ahead of print 2001. DOI: 10.1302/0301-620X.83B6.0830883.
9. Turgut A, Kalenderer Ö, Bozoğlan M, et al. Flexion type supracondylar humerus fractures: 12 year experience of a pediatric orthopedics clinic. Eklem Hast ve Cerrahisi 2015; 26: 151–157.
10. Amir S, Jannis S, Daniel R. Distal humerus fractures : a review of current therapy concepts. Epub ahead of print 2016. DOI: 10.1007/s12178-016-9341-z.
11. Madhuri V, Balakumar B. A retrospective analysis of loss of reduction in operated supracondylar humerus fractures. Indian J Orthop. Epub ahead of print 2012. DOI: 10.4103/0019-5413.104219.
12. Ullah I, Khan LA. Results of conservative treatment of displaced extension - Type supracondylar fractures of humerus in children. J Postgrad Med Inst 2009; 23: 95–98.