Research Article

Profile of neglected supracondylar humeral fractures in Prof. Dr. Soeharso orthopaedic hospital Surakarta, Indonesia (january 2018 - december 2018)

Tito Sumarwoto, Seti Aji Hadinoto, Savero Iman Hari Suko

Department of Orthopaedic & Traumatology, Prof. Dr. R. Soeharso Orthopaedic Hospital - Faculty of Medicine
Sebelas Maret University Surakarta, Indonesia

ABSTRACT

Introduction: The supracondylar humeral (SCH) fracture is a fracture that occurs in the distal part of the humeral bone at the level of the condyle, which passes through the olecranon fossa. SCH fracture is the most common fracture in the elbow of children and is usually treated in an emergency setting, whether using close reduction or open reduction, and percutaneous pining. However, the treatment often delayed for various reasons.

Object: This study was to analyze the profile of patients with neglected SCH fractures in Prof. Dr. R Soeharso Orthopaedic Hospital, Surakarta, Indonesia in 2018.

Materials and Method: We retrospectively reviewed the hospital medical records of all admitted patients with neglected SCH fractures from January 2018 to December 2018 in Prof. Dr. Soeharso Orthopaedic Hospital Surakarta.

Results: Eight patients with neglected SCH fractures, 7 males (87%) and 1 female (13%). Seven patients were children and one patient was a young adult. Four cases were extension type and 4 cases were flexion type. In cases of deformities: 5 cases (62%) were varus deformity, 2 cases (25%) were valgus, and 1 case (13%) was s-shape deformity. We did open reduction and inserted k-wires in all patients, 62% (n=5) was lateral approach, 25% (n=2) was posterior approach, and 13% (n=1) was medial approach. The average time the patients seek the treatment was 3.875 weeks, varies starting from 2 weeks - 7 weeks. We compared ROM of the elbow before and after surgery, and found that surgery was able to improve ROM in patients with neglected SCH fractures. However, in some patients, the postoperative ROM cannot be optimal.

Keywords: Supracondylar humeral fractures, neglected fractures, elbow
https://doi.org/10.31282/joti.v3n3.64

Corresponding author : Tito Sumarwoto, MD. Email : tito.ortho@gmail.com

INTRODUCTION

Supracondylar humeral (SCH) fracture is the commonest elbow fracture in children[1–4]. This fracture comprises 55% to 75% of elbow fractures and approximately 3% of all fractures in children[3]. In developing countries, however, treatment delays are common (between 10% and 20% of cases)[1,3]. Neglected or late presentation is defined as roughly more than 2 days after injury, and objectively is defined as when a callus is visible in X-ray but the fracture line is still visible[3]. The objective of this retrospective study was to analyze epidemiological data of neglected SCH fractures and to assess functional outcomes after delayed treatment of SCH fractures.

MATERIALS AND METHODS

Data collection

The data of all admitted patients with neglected SCH fractures from January 2018 to December 2018 were collected from the medical records of Prof. Dr. R. Soeharso Orthopaedic Hospital. The data consisted of age, gender, mechanism of injury, deformities, surgery approach, time of injury until treatment, and range of motion (ROM) of pre- and post-surgery.

Setting and participants

The data of all patients with neglected SCH fractures in Prof. Dr. R. Soeharso Orthopaedic Hospital, Surakarta, were collected retrospectively from January 2018 to December 2018.

RESULTS

There were 8 patients with neglected SCH fractures, consisted of 7 males (87%) and 1 female (13%) as seen in Figure 1. The patient's age distribution was shown in Figure 2, and the most patients were children.

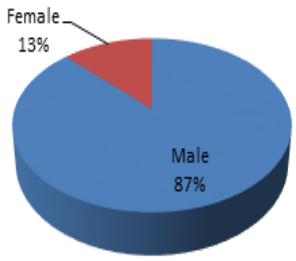

Figure 1. The frequencies of neglected SCH fractures by sex.

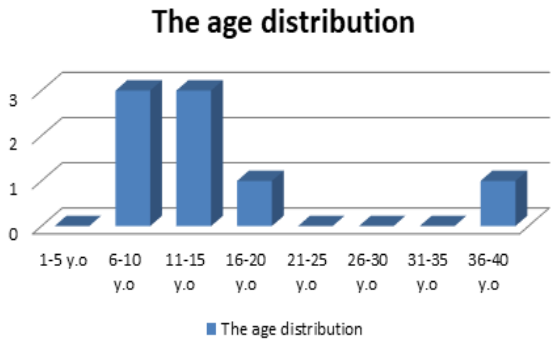

Figure 2. The age distribution of neglected SCH fractures

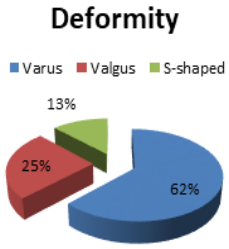

Figure 3. Distribution of neglected SCH fractures by deformity

Regarding the mechanism of injury, 4 cases were extension type and 4 cases were flexion type. In cases of deformities: 5 cases (62%) were varus deformities, 2 cases (25%) were valgus deformities, and 1 case (13%) was s-shape deformity (Figure 3).

For all cases, we performed reconstruction surgery. Open reduction internal fixation had been performed and cross pinning had been inserted to fixate the fractures. We used various approaches for these patients, 5 patients were lateral approach (62%), 2 patients were posterior approach (25%), and 1 patient was medial approach (13%).

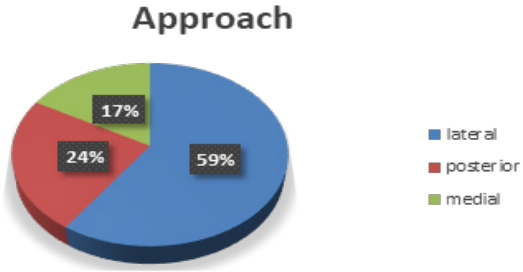

Figure 4. Distribution of surgery approach for ORIF neglected SCH fractures.

The time of injury until the treatment varies in these patients, from 2 weeks to 7 weeks with an average of 3.875 weeks, as described in the Table 1.

Table 1. Comparison of ROMs of elbow before and after surgery

Case	pre-operative	post-operative	time of injury
1	0-90	0-110	3 weeks
2	0-90	0-110	4 weeks
3	20-70	0-110	4 weeks
4	0-70	0-110	3 weeks
5	60-70	20-110	7 weeks
6	0-90	0-100	4 weeks
7	0-90	0-110	2 weeks
8	30-90	0-100	4 weeks

We compared the ROMs of the elbow before and after surgery, and the results were shown in Table 1. The ROMs after the surgery improved compared to the ROMs before the surgery.

DISCUSSION

Supracondylar humeral (SCH) fracture is the most common fracture around elbow joint in paediatric population. They constitute around more than half of paediatric elbow fractures, 3% of all the paediatric fractures, with peak incidence at the age of 5 to 7 years. These fractures affect mainly the male gender and occur prevalently in consequence of an extension mechanism[1–5]. The neglected/late state is when the patients seek treatment more than 2 days or more than 14 days after the fractures occurred and objectively the callus appears in the X-ray, meanwhile the fracture lines are still exist [3,6].

In our series, peak incidence was at the age of 10 to 15 years, boys had higher incidence than girls. We also had same patients between extension and flexion mechanism.

Delayed treatment of supracondylar fracture of the humerus is very common[1–3]. Elbow fractures which present two days after the injury occurred are termed as neglected/late presentation. This may be attributed to delay in seeking medical attention due to poor transport facilities and unsatisfactory health delivery system or negligence of medical staff and overcrowding of emergencies. Patients' lack of awareness and visiting quacks for initial treatment further leads to the delay in proper management of these fractures[2,3,7]. Patients also present with edema, the cause of which may be due to improper attempt at healing by a quack[2]. Cubitus varus is common in 10%–30% of cases regardless of the method of treatment. This deformity does not develop into remodelling[3]. In accordance with our study, the most deformity was varus.

The treatment modalities implicated in the neglected presentation cases are as follows[3] :

(i) Continuous traction of the arm to gradually re duce the fracture, which avoids the risk of vas cular complications and iatrogenic ulnar nerve injury but has the disadvantage of prolonged hospital stay
(ii) Early wedge osteotomy 1–4 months after injury but before adolescence
(iii) Open reduction and internal fixation

There is not much literature describing specific treatment guidelines for neglected presentation of SCH fracture in children, so the treatment method remains controversial[1,3.] We did the surgery by doing open reduction internal fixation with cross pinning insertion or TBW. Lateral approach was the most approach we used. Reitman *et al*. reported that 78% (fifty-one) of sixty-five patients treated with open reduction (through either medial or lateral approach) had excellent or good results according to the criteria of Flynn *et al*[8]. On the other hand, the posterior approach is generally not recommended because of the high rate of loss of motion and, more importantly, the risk of osteonecrosis secondary to disruption of the posterior end arterial supply to the trochlea of the humerus[7,8].

Regarding the neglected state, our eight patients came to seek the treatment starting from 2 weeks to 7 weeks, with an average of 3.875 weeks. The callus was already developed but the fracture line was still exist.

We compared the ROM of the elbow before and after surgery; and there was an increasing in ROM after surgery compared to before surgery. However, in some patients, the post-operative ROMs cannot be optimal. Delay in management of SCH fracture results in fibrosis of the joint. This stiffness, which is present pre-operatively, might have some influence on the postoperative results. Increased incidence of elbow stiffness was observed in patients after their fractures were reduced by open reduction approach. Stiffness associated with open reduction was not found in patients treated by closed reduction and internal fixation. Limited mobility of injured elbow joint and prolonged immobilization post-operatively also causes stiffness of the joint leading to decrease in range

of movement[2].

SUMMARY

Delayed treatment for SCH fracture is common in developing countries. In our study, reconstruction surgery can improve ROM of the elbow. However, in some patients, the post-operative ROMs cannot be optimal, due to the association with fibrosis of the joint.

REFERENCES

1. Yaokreh JB, Odehouri-Koudou TH, Tembely S, et al. Delayed treatment of supracondylar elbow fractures in children. *Orthopaedics and Traumatology: Surgery and Research*. 2012;98(7):808-812. doi:10.1016/j.otsr.2012.07.005
2. Khan J, Ahmed R, Akhtar RR, Batool K, Riaz H. Effect of Delay in Operative Treatment on the Range of Motion in Supracondylar Humerus Fracture. *Journal of Rawalpindi Medical College (JRMC)*. 2017;21(1):51-56.
3. Shah RK, Rijal R, Kalawar RPS, Shrestha SR, Shah NK. Open Reduction and Internal Fixation of Displaced Supracondylar Fracture of Late Presentation in Children: A Preliminary Report. *Advances in Orthopedic Surgery*. 2016;2016(i):1-6. doi:10.1155/2016/9256540
4. Ali N, Bhat A, Bangroo FA, et al. Epidemiological Study of Paediatric Supracondylar Humeral Fracture : Experience at a Tertiary Care Centre of North India. *International Journal of Biomedical and Advance Research IJBAR*. 2014;05(09):425-428. doi:10.7439/ijbar
5. Kharat AA, Biraris SR, Dhaniwala NS, Shinde GJ, Bhoj P. A Comparative study of management of displaced Gartland III supracondylar fracture humerus in children. *Journal of Medical Thesis*. 2017;5(1):12-17. doi:10.13107/jmt.2347-5595/0154
6. Sumarwoto T, Hadinoto SA, Pranandaru H, Andhika H, Rhatomy S, Utomo P. Short-term Follow-up of Early Reconstructive Surgery Management in Neglected Supracondylar Humeral Fractures. *Open Access Macedonian Journal of Medical Sciences*. 2021;9(Jan 21):24-28. doi:http://doi.org/10.3889/oamjms.2021.5577
7. Anjum R, Sharma V, Jindal R, Singh TP, Rathee N. Epidemiologic pattern of paediatric supracondylar fractures of humerus in a teaching hospital of rural India: A prospective study of 263 cases. *Chinese Journal of Traumatology - English Edition*. 2017;20(3):158-160. doi:10.1016/j.cjtee.2016.10.007
8. Omid R, Choi PD, Skaggs DL. Supracondylar humeral fractures in children. *Journal of Bone and Joint Surgery - Series A*. 2008;90(5):1121-1132. doi:10.2106/JBJS.G.01354