Case Report

Neglected Traumatic Posterior Hip Dislocation In a 4-Years-Old Child: A Case Report

Renanda Muki Putra[1], Arsanto Triwidodo[2], Putu Mira Indrayanti[3], Danarto Hari Adhimukti[4]

[1]General Practitioner, Koja District Hospital, Jakarta
[2]Spine Consultant, Department of Orthopaedic and Traumatology, Faculty of Medicine Indonesia University, Koja District Hospital, Jakarta
[3]Orthopaedic Surgeon, Department of Orthopaedic and Traumatology, Faculty of Medicine Universitas Indonesia, Koja District Hospital, Jakarta
[4]Resident, Department of Orthopaedic and Traumatology, Faculty of Medicine Universitas Indonesia, Koja District Hospital, Jakarta

ABSTRACT

Introduction: Traumatic hip dislocation in pediatrics is relatively rare. Low-energy mechanisms of injuries such as trivial falls and slips are the usual causes, especially in the young age group (<5 years). Long-term complications may arise, especially if the hip dislocation is neglected. The reduction of a hip dislocation that has been neglected becomes more difficult over time.

Case Report: We present a 4-year-old male patient with a neglected traumatic posterior hip dislocation after falling from a parked motorcycle two weeks before admission. The posterior hip dislocation was diagnosed by physical examination and X-Ray. There was no disturbance in either the neurological or vascular status of the patient. The dislocation was reduced by closed reduction using the Allis maneuver.

Result: Post-reduction radiograph using X-ray showed a concentric reduction, and six weeks of immobilization using hip spica were initiated afterward. The patient showed normal gait and a painless range of hip movement without complications at two months follow-up

Keywords: neglected, traumatic, posterior hip dislocation, children
https://doi.org/10.31282/joti.v4n3.82

Corresponding author : Renanda Muki Putra, MD. Email: renandamuki@gmail.com

INTRODUCTION

Traumatic posterior hip dislocation is infrequent in pediatrics. accounts for about less than 6%.[1,2,3] The causing trauma usually results from low-energy mechanisms, especially in children under five. This is mostly due to the laxity of their joints and their soft pliant cartilage compared to adults.[1,2,4] AVN of the head of the femur, sciatic nerve injury, degenerative arthritis, and recurrent dislocation are among the complications of posterior hip dislocation and may be associated with delayed reduction. Neglected in musculoskeletal injuries can be defined as injuries that are presenting late, lack or without comprehensive treatment and the time frame varies between body regions.[5] Neglected hip dislocation is still vaguely defined in the literature. A study by Garret et al. (1979) stated that a dislocated hip that was not reduced in 72 hours was called old unreduced hip dislocation.[6,7] Also, closed reduction of a dislocated hip that has been neglected becomes less possible over time due to fibrous tissue formation after the trauma.[8] Therefore, early diagnosis and prompt reduction are of utmost importance.[1,2,9,10,11]

PRESENTATION OF CASE

A 4-year-old boy was brought by his caregiver to our hospital with pain felt in his left thigh. He fell from a parked motorcycle two weeks before admission and had difficulty extending his left leg after the incident. The left hip was internally rotated, adducted, and slightly flexed with tenderness over the joint on examination. The left leg also appears shorter than the opposite leg by approximately 2 cm (Figure 1A). There were no distal neurovascular disturbances. The hip range of movement was limited on both active and passive examinations due to pain. Radiological evaluation using hip X-ray showed a displacement of the femoral head from the acetabulum to a superior and lateral direction without concomitant fracture (Figure 1B). Closed reduction of the hip using the Allis maneuver was then performed under general anesthesia. Post-reduction radiograph using another X-ray showed an anatomical reduction of the dislocated hip (Figure 3). We then immobilized the reduced dislocated hip with a hip spica for six weeks before weight-bearing (Figure 4). The patient showed normal gait, no pain, and a full range of hip movement at the follow-up two months later (Figure 5). We also found no signs of early AVN on the follow-up hip X-Ray. We advised the patient and his caregiver to remain on follow-up.

DISCUSSION

Traumatic hip dislocation is infrequent in pediatrics.[1,2,3] Trivial fall or slip (a low-energy mechanism of injury) is the usual cause, especially in the young age group (<5 years). In older children (>5 years), hip dislocation is more often caused by an athletic injury or a motor

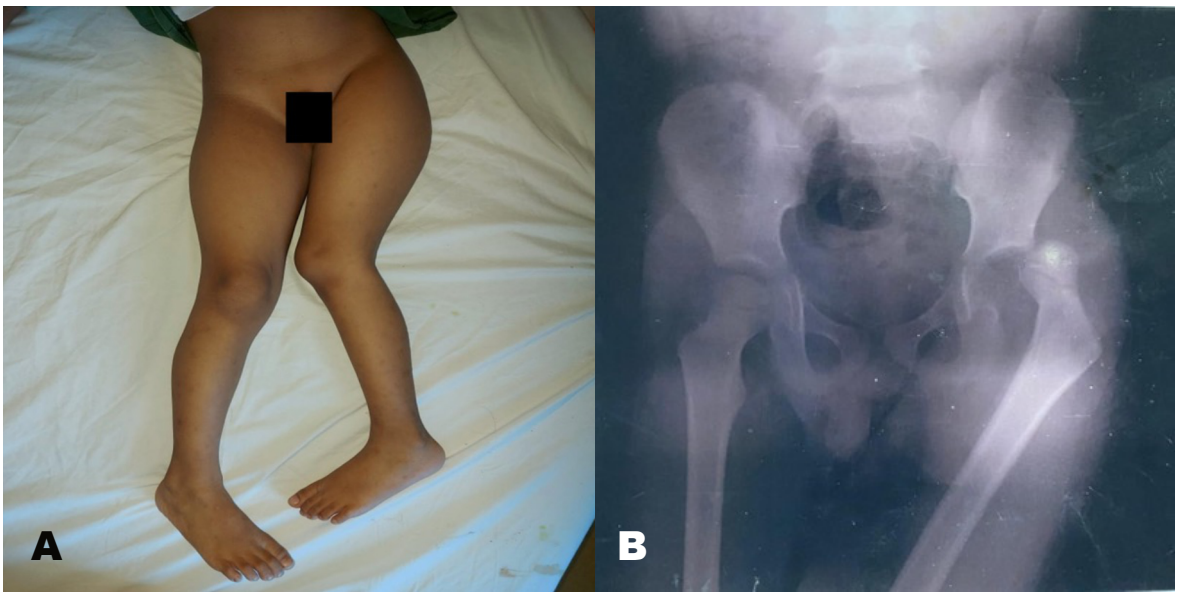

Figure 1. The patient's left hip before reduction (A). A posterior hip dislocation without associated fracture was seen on the AP hip radiograph (B)

vehicle accident (high energy mechanism of injury).[1,4,9,10,12] Hip dislocation in children can be classified into posterior, anterior, and central. Posterior dislocations constitute 75–90% of hip dislocations in children.[1]

A force that directs the femur posteriorly causes the typical posterior dislocation. Flexion, adduction, and medial rotation of the involved thigh are characteristics of posterior hip dislocation. The dislocated hip makes the leg on that same side appear shorter than the opposite leg. The examiner may palpate the femoral head posteriorly. The leg does not rest in a specific position in a central hip dislocation, and there is no leg length discrepancy. In an anterior hip dislocation, the dislocated limb may appear in a flexed, abducted, or externally rotated position. The examiner can palpate the femur head in the region of the obturator foramen, and the dislocated limb may appear longer than the contralateral side.[1] The examiner should also look for possible sciatic nerve and femoral nerve injuries that may occur in posterior and anterior hip dislocations, respectively.[1,2,10]

An AP view of a pelvic radiograph should be obtained to exclude associated injuries. In addition, more advanced imaging like MRI and CT can further exclude associated fractures and injuries that are not visible on X-ray. The radiographic finding of posterior hip dislocation is the typical displacement of the femoral head from the acetabulum in a superior and lateral direction.[1,2,10] Our patient is under the age of five, and the causative trauma mechanism was trivial. The characteristics of posterior hip dislocation were present, including a flexed, adducted, and medially rotated thigh. The AP pelvic radiograph showed displacement of the femoral head in a superior and lateral direction. Therefore, our findings were in accordance with the literature.

In our case, we consider the patient's condition to be an untreated or neglected hip dislocation because the injury occurred late and was not treated.[5] The time frame was in concordance with the criteria by Garret et al. (1979), because of the prolonged dislocation to a reduction time interval (2 weeks).[6] To the best of our knowledge, the definition of "neglected hip dislocation" is still vaguely defined in the literature, or there is no clear agreement. Early reduction by the closed method under general anesthesia is sufficient in most hip dislocation cases, hence why we chose to do so in our case. If the closed reduction fails or there are concomitant fractures, an open reduction should be considered.[1] Another piece of literature suggests that three trials of closed reduction be tried before an attempt at open reduction.[12,13] The treatment of a hip dislocation that has been neglected becomes more difficult over time. This difficulty may be due to fibrous tissue

Figure 2. An anatomical reduction of the left hip joint was seen on the post-closed

Figure 3. The patient's left leg was immobilized with a hip spica

formation in the acetabulum, making closed reduction less possible.[8] Fibrous tissue begins to develop as early as 3 weeks and later filled the capsule by 8-10 weeks in an experimental animal study, and similar findings from another study. Hence, it is suggested that a closed reduction can still be done on a dislocated hip in less than 3 weeks.[6,7,11,14,15,16]

Furthermore, children, especially the younger groups (under the age of 5 years), whose acetabulum is mostly soft, pliant cartilage and tends to have more laxity in their joint compared with adults, require minor trauma to dislocate the joint. Thus, it's mostly not associated with other injuries or soft tissue or osteochondral interposition that may have made the close reduction more difficult.[17] Therefore, despite being neglected, we were still able to do a closed reduction on the patient's dislocated hip. We hypothesized that our case findings were no different from or in concordance with the literature just mentioned. These findings include: 1) the mechanism of injury of our patient was relatively minor (he fell from a parked motorcycle); 2) the younger age profile (under the age of 5); and 3) supposedly unabundant fibrous tissue formation (less than 3 weeks).

We treated the patient with closed reduction under general anesthesia using Allis maneuver because it's relatively one of the easiest, the most common, and the most effective treatments based on literature and our own experience. In this method, the patient's hip and knee are flexed 90 degrees, slightly adducted, and medially rotated. The surgeon then gives anterior traction by holding the patient's knee with one or both of their hands while the assistant holds the patient's anterior superior iliac spine.[1,12] Post-reduction X-ray showed an anatomical reduction. For the follow-up, we used criteria developed by Garret et al. (1979) to assess the follow-up result as excellent, good, fair, or poor. A painless, non-limping hip with a full range of hip movements is considered an excellent result. A painless, non-limping range of hip movements of 75% is considered good. A non-disabling pain with a moderate limp and a 50% range of hip movement is considered a fair result. A poor result is defined as disabling pain and markedly limited hip movement.[6] Our patient was excellent at follow-up.

Figure 4. Xray of both hips at two months follow up

There is some literature with a case similar to ours regarding the dislocation to a reduction time and the chosen reduction method. Baidoo and Adegah (2017) reported similar findings in their study. Their patient was also successfully treated with closed reduction using Allis maneuver, with two weeks being also the dislocation to time interval. Their patient was then followed up by six months, with no limping and painless range of motion.[18] A study by Hung (2012) reported 22 patients with five patients having a similar dislocation time interval to ours (interval of 12 days to 17 days). The five patients were treated by closed reduction using the Allis maneuver. The results were excellent in two, good results in two, and fair results in one.[15] These findings further support the idea of still being able to reduce the dislocation within 3 weeks.

There have been no conclusions regarding rehabilitation or when weight-bearing will be allowed. According to some studies, six weeks of immobilization with a spica cast before the patient is allowed to bear weight is sufficient for healing the soft tissue.[1,2,10] Traumatic hip dislocations in children can lead to complications, especially if the reduction is delayed. AVN of the head of the femur, sciatic nerve injury, degenerative arthritis, and recurrent hip dislocation are among the complications. AVN of the head of the femur is the most common complication. Factors that may be associated with the development of AVN are severe trauma and a delay in reduction of 6 hours or more from the time of dislocation.[1] The risk of AVN can increase by 20 times for every 6 hours of delay in its reduction.[19] Serial follow-up radiographs should be checked for at least two years after the original dislocation/trauma because radiographic findings of AVN can develop up to two years later.[1] Our patient had no complications at his last

follow-up and was advised to check for any potential complications regularly.

CONCLUSION

Traumatic hip dislocation is infrequent in pediatrics. The mechanism of injury is usually trivial. Early diagnosis and prompt reduction should be done early for good outcomes, thus reducing the risk of potential complications. Long-term follow-up and monitoring are necessary.

REFERENCES

1. Herring JA. Tachdjian's pediatric orthopedics: from texas scottish rite hospital for children. 6th ed. Vol 2. Philadelphia, PA: Elsevier. 2022:1294-303.
2. Meena et al. Traumatic posterior hip dislocationin a 16-month-old child: A case report and review of literature. Chinese J Traumatol- English Ed. 2012;15(6):382–4.
3. Bressan S, Steiner IP, Shavit I. Emergency department diagnosis and treatment of traumatic hip dislocations in children under the age of 7 years: A 10-year review. Emerg Med J. 2014;31(5):425–31.
4. Van de VA et al. Posterior Hip Dislocation in Children: A Mild Traumatic Event. CaseReport and Review of Literature. Orthop Res Online J. 2018;4(5):436-9.
5. Gill KA, Shah FA. Neglected Musculoskeletal Trauma. J Pak Orthop Assoc 2021;33(2)
6. Garrett JC, Epstein HC. Harris WH. Treatment of unreduced traumatic posterior dislocation of the hip. J Bone Joint Surg Am. 1979;61(1):2–6.
7. Prakash et al. Neglected Posterior Dislocationof Hip in Children-A Case Report. J Orthop Case Reports. 2014;4(2):21–4.
8. Miltner LJ,Wan FE. Old traumatic dislocations of the hip with reference to operative treatment. Surg Gynec Obst. 1933:56, 84.
9. Başaran et al. Treatmentand results in pediatric traumatic hip dislocation: Case series and review of the literature. Ulus Travma Acil Cerrahi Derg. 2014;20(6):437–42.
10. Furuya et al. Traumatic Dislocation of the Hip in a Child Caused by Trivial Force for Age. Case Rep Orthop.2014;2014:1–4.
11. Pai VS, Kumar B. Management of unreduced traumatic posterior dislocation of the hip: heavy traction and abduction method. 1990;21(4):225–7.
12. Clausen et al. A Rare Case of a Traumatic Posterior Hip Dislocation in a 3-Year-Old Boy: A Case Report and Review of the Literature. Case Rep Orthop. 2020;2020:1-6.
13. Coll et al, Traumatic hip dislocation in childhood. Hip International. 2010 Oct;20(4):524-8.
14. Kumary S, Jain AK. Open reduction of late unreduced traumatic posterior hip dislocation in 12 children. Acta Orthopaedica Scandinavica. 1999 Jan 1;70(6):599-602.
15. Hung NN. Traumatic hip dislocation in children. J Pediatr Orthop Part B. 2012;21(6):542–51.
16. Lahfaoui M. Traumatic dislocations of the hip in children About 11 cases and literature review. J Surg Surg Res. 2020;6(1):022–6.
17. Massoud EI. Neglected traumatic hip dislocation: Influence of the increased intracapsular pressure. World Journal of Orthopedics. 2018 Mar 18;9(3):35.
18. Baidoo KP, Adegah B. Delayed diagnosis of traumatic posterior hip dislocation in a 6-year-old girl with 6 years follow up: a case report. Int Surg J. 2017;4(10):3511-4.
19. Mehlman et al. Traumatic hip dislocation in children. Long-term follow-up of 42 patients. Clin Orthop Relat Res. 2000;(376):68-79.