

Literature Review

The Pathomechanics, Clinical Assessment and Management of Hallux Valgus: A Literature Review

Natasha Valerie¹, Putri Maya Sari¹, Edlyn Amadea Widjaja^{1,3}, Erica Kholinne^{2,3}

¹Faculty of Medicine, Atma Jaya Catholic University of Indonesia

²Faculty of Medicine, Universitas Trisakti, Jakarta, Indonesia

³Department of Orthopedic Surgery, St. Carolus Hospital, Jakarta, Indonesia

Article Info :

Abstract

Article History :

Submission: July 22, 2023

Revision: September 22, 2023

Accepted: September 22, 2023

Keywords :

Hallux valgus
Forefoot deformity
Bunion
Foot and Ankle

Corresponding Author :

Erica Kholinne, MD, Ph.D

E-mail: erica@trisakti.ac.id

Hallux valgus, the most common forefoot deformity, can restrict movement and cause pain. Several internal and external variables contribute to the development and advancement of the hallux valgus. Conservative and surgical treatment methods must be determined depending on the severity of the bunion, as well as any concomitant foot and ankle diseases. Only when the condition is still in its early stages can conservative management stop the progression of hallux valgus. Surgical treatment of hallux valgus is technically difficult and carries a high risk of recurrence and complications.

Introduction

Hallux is valgus (HV), generally known as a bunion which means turnout in Latin was first described by Carl Hueter.¹ Hallux valgus (HV) or bunion is the most prevalent deformity of the legs. HV often develops when the first toe thumb deviates to the lateral and metatarsal I deviate to medial.² The clinical image of hallux valgus is a lateral deviation of the proximal phalanx and a medial deviation of the first metatarsal head as a result of adduction of the first metatarsus, known as the metatarsus primus varus.²

Epidemiology & Etiology

The prevalence of this disease was 23% in people 18 to 65 years of age and increased by 36% in adults 65 years of age.³ Women are more likely than men to have hallux valgus, with ratios as high as 15:1.2 compared to the barefoot population, the prevalence of this disorder is also higher among people who wear shoes, especially those who wear high heels or shoes with a small toe space (typically observed in women's shoes).^{4,5} Intriguingly, in a study comparing men and women in a

barefoot society, women were shown to have twice the chance of developing hallux valgus.³ Some studies described that hallux valgus may develop in individuals who do not wear tight-fitting shoes or even often bare shoes can be associated with a congenital predisposition.^{6,7}

In the United States, there are 64 million people who suffer from hallux valgus, however, there are no statistics on the total population of hallux valgus in Indonesia. However, studies have been conducted on certain population groups, such as research conducted by Soemarmo et al. with the female population working in supermarkets, indicating the occurrence of hallux valgus up to 25.25% in the population of high-heel users compared to flat-heels users, which is only 10.87%.⁸

Although the precise etiology of HV is unknown, several factors support the presence of HV. These factors are classified into two types: internal and extrinsic factors. Intrinsic factors include heredity, gender, ligament weakness, age, metatarsal primus varus status, metatarsal architecture, pes planus, and a tight Achilles tendon. Meanwhile, a shoe model and weight load are the extrinsic components.⁹

Pathomechanics

Although the etiology of hallux valgus is complex, it is believed to be caused by an imbalance between extrinsic and intrinsic muscles, as well as the ligaments of the legs.¹⁰ Hallux valgus commonly arises in phases.¹² These phases do not always occur, respectively, but simultaneously. 1. Since the medial sesamoid and medial collateral ligaments are the only medial supporting structures of the first metatarsophalangeal joint, their failure is the "early and essential lesion".¹³ 2. The metatarsal head can then move medially, detaching from the sesamoid structure. This movement can be aided by an oblique or unstable tarsometatarsal joint.^{11,14} 3. As it is connected at its base to the sesamoids, the deep transverse ligament (via the plantar plate), and the adductor hallucis tendon, the proximal phalanx shifts into a valgus position. 4. The crista and cartilage may be eroded by the metatarsal head, which rests on the medial sesamoid. Although it is immobile, the lateral sesamoid may appear to be in the intermetatarsal region. 5. Due to pressure from the shoes on a prominent medial eminence, the bursa covering it may get thicker.^{11,14} 6. The extensor and flexor hallucis longus tendons appear in the bowstring laterally, increasing valgus displacement and occasionally acting as proximal phalanx dorsiflexion.¹⁵ 7. The muscle forces operating across the metatarsal head lead it to pronate as it detaches from the sesamoid apparatus.¹¹ 8. The abductor hallucis normally resists proximal phalanx valgus but becomes ineffective as its

medial and plantar attachment rotates inferiorly. Because the adductor hallucis is laterally connected to the plantar surface, it tends to draw the phalanx into pronation while also anchoring its base. 9. The weaker dorsal metatarsophalangeal joint capsule is not supported by tendons and rotates medially with pronation, providing low stability. 10. Plantar pressure can be transferred laterally by elevating the metatarsal head with medial motion. The fifth metatarsal, which is relatively movable, may also play.¹¹

Diagnosis

History

Hallux valgus has a chronically progressive onset. Bunions, aesthetic problems, and shoes that require to wear shoes are the three most frequently reported problems by patients. Patients typically report acute pain in the MTP joint, and difficulty with shoe wear due to the medial eminence.⁵ As the disease progresses, the frequency, duration, and severity of the discomfort gradually increase. Patients often complain of swelling, tingling, or burning in the dorsal area due to the compression of the digital nerve. This burning and tingling sensation shows the presence of medial dorsal cutaneous nerve neuritis, which could be caused by compression of the deformity. Patients may also have blisters, ulcers, interdigital keratosis, and sensitive skin near abnormalities. These problems can result in severe morbidity and frequently prevent the patient from engaging in physical exercise.⁵

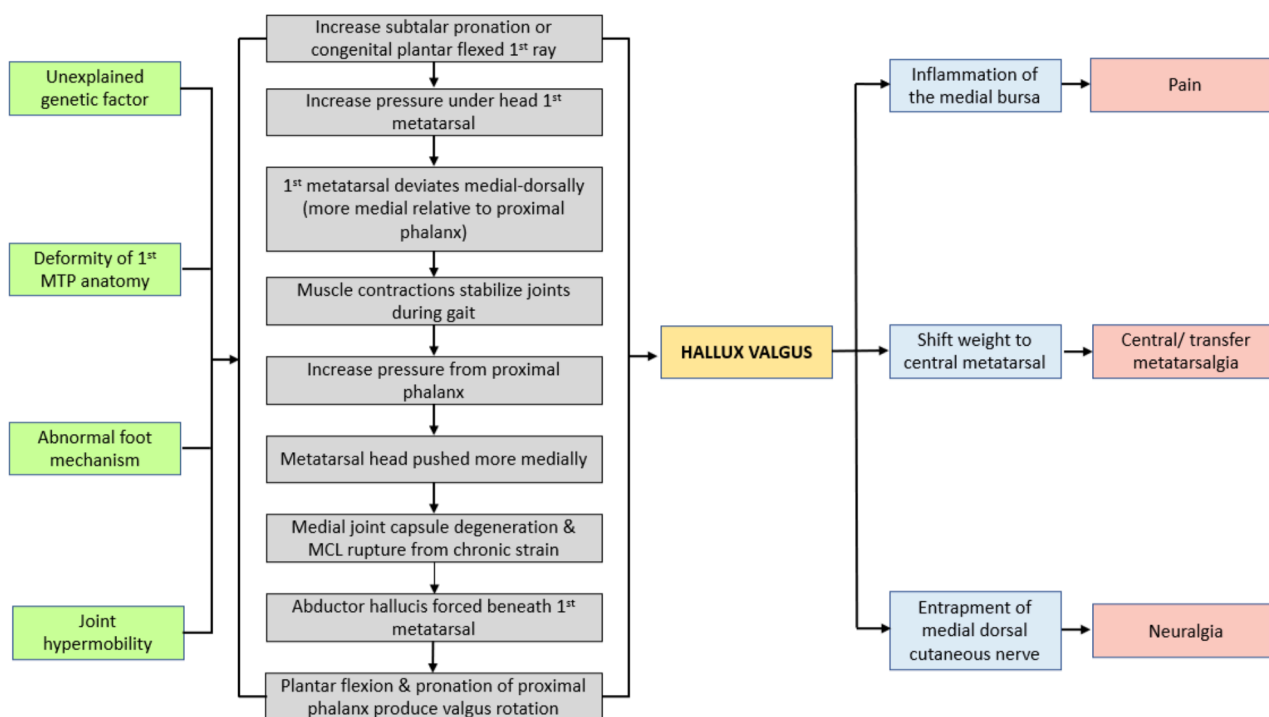


Figure 1. Pathophysiology and mechanism Hallux valgus

Physical examinations

The physical examination revealed: 1. Hallux rests in the valgus position and pronates as a result of the force generated by the deformity; 2. the entire first ray section to evaluate the range of motion (ROM) of the first metatarsophalangeal (MTP) (normal plantarflexion $<15^\circ$ and dorsiflexion $65^\circ - 75^\circ$), the first tarso-metatarsal, callus formations, sesamoid/ arthritis pain; 3. check other deformities such as pes planus, lesser toe deformities (mallet toe, hammer toe, claw toe, curly toe, and crossover toe), midfoot and hindfoot conditions. The severity based on the ROM of the first MTP is: 1. normal ($<15^\circ$); 2. mild ($<20^\circ$); 3. moderate ($20^\circ - 40^\circ$); 4. severe ($>40^\circ$).^{16,17}

Additional Examinations

Radiological findings

Standing position (weight-bearing AP, lateral and oblique views) may reveal metatarsal, hallux angulation, and lateral displacement of sesamoids. On the medial section of metatarsal I and metatarsal II, as well as in the proximal phalanx I, imaginary lines are depicted. Normally, the intermetatarsal angle is 9 degrees and the valgus angle in the MTP joint is 15 degrees. Angulations that are greater than the normal angle will result in the diagnosis of hallux valgus. (2) There are 4 classifications based on hallux valgus angle (HVA)/intermetatarsal angle (IMA): 1. normal ($<15^\circ / 9^\circ$); 2. mild ($15^\circ - 30^\circ / 9^\circ - 13^\circ$); 3. moderate ($30^\circ - 40^\circ / 13^\circ - 20^\circ$); 4. severe ($>40^\circ / >20^\circ$).^{2,5}

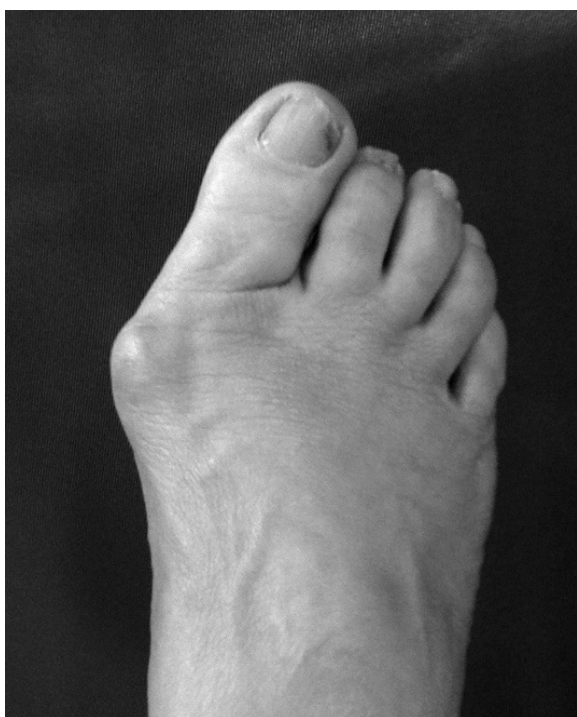


Figure 2. Deformity of Hallux Valgus on 1st MTP joint

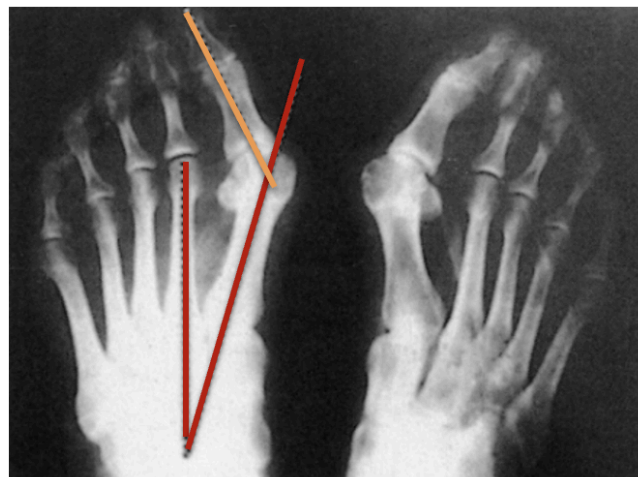


Figure 3. Radiologic picture of Hallux valgus. Red line is intermetatarsal angle (IMA). Orange line is Hallux valgus angle (HVA).

Treatments

Nonsurgical treatments

The American College of Foot and Ankle Surgeons still encourages nonsurgical or conservative therapy before contemplating more invasive therapies. If medical intervention fails, surgical repair should be taken into consideration.¹⁶ The patient's specific complaints are necessary to be determined. Pain without a cosmetic concern is a proper indication for conservative treatment. Conservative treatment options for hallux valgus include activity modification, soft and comfortable wide-toe box shoes, spacers between the big toe and the second toe, and avoidance of tight and high-heeled shoes.^{18,19} Bunion pads can help alleviate symptoms even more.⁶ Although orthotics may help reduce pain, they have not been demonstrated to effectively prevent the advancement of hallux valgus.^{20,21} At one year's follow-up in a randomized controlled trial comparing surgery, orthosis, and watchful waiting, 83%, 46%, and 24% of patients in the surgery, orthosis, and control groups, respectively, reported improvement in their pain symptoms.²² The surgical group had the fewest uncomfortable days, cosmetic disruption, and footwear problems, as well as the best functional status and treatment satisfaction.²² If symptoms continue despite conservative treatment, the revision surgical technique should be selected using the same criteria as for the basic HV deformity.²³

Surgical treatments

Non-surgical therapeutic failures, recurring infections, and ulcerations are all indications for surgery.¹⁸ Meanwhile, surgical correction for cosmetic deformities alone is not advisable because of the recovery time and the potential for complications associated with operative correction.¹⁶ The planned

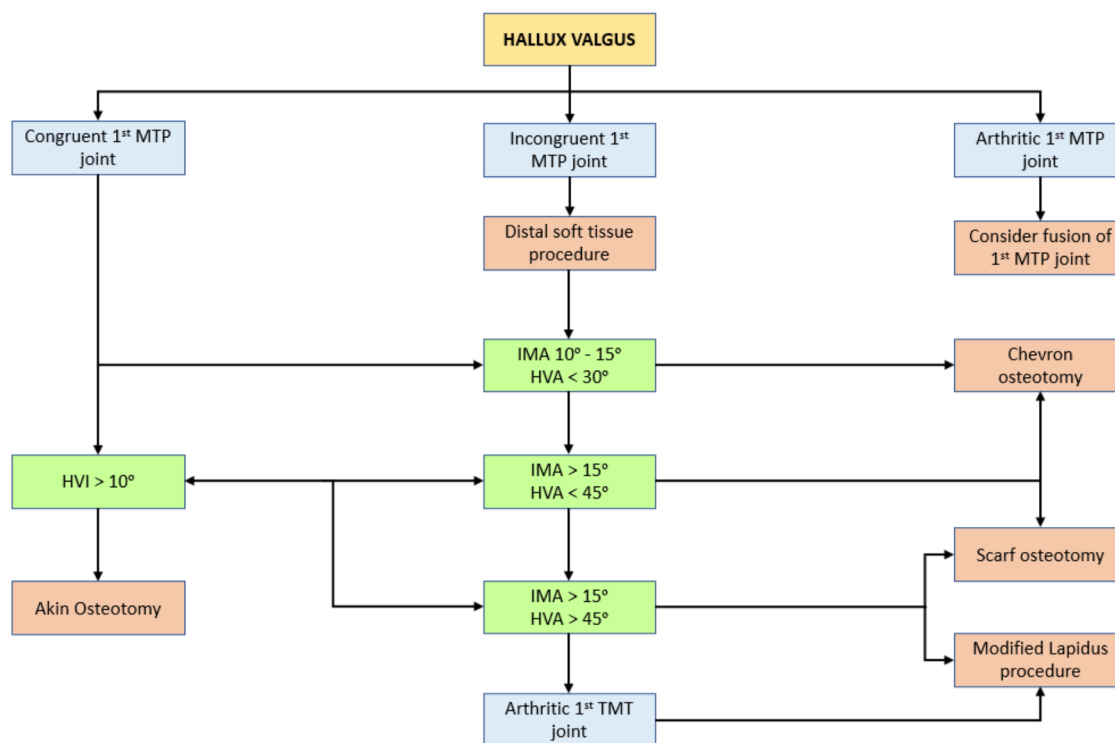


Figure 4. Operative treatment algorithm

operation is determined by the severity and extent of the malformation. In general, there are four types of surgeries: 1. metatarsal osteotomy, 2. proximal phalanx osteotomy, 3. fusion procedures, and 4. resection arthroplasty. Soft tissue procedures are usually indicated for a very mild deformity in young patients. Surgical correction is best performed until skeletal maturity.² The decision as to which type of correction is chosen will depend on 1. MTP congruency, 2. the presence of arthritic at the MTP, 3. IMA and 4. HVA.²⁴

According to research, distal osteotomy is associated with reduced discomfort and increased ability to resume exercise in the medium to long term. Patient satisfaction with post-distal osteotomy HV is generally good (75%), with a complication rate of 10%.² If the deformity is minor (less than 25°), it can be repaired by mending the surrounding soft tissues or by metatarsal osteotomy. If a congruent articulation radiograph is found, the deformity is most likely caused by bone and can be corrected with distal osteotomy. On the contrary, if the MTP articulation is not congruent and the deformity is already present in the joint, this is an indicator that a realignment is required.²

If the articulation is still congruent, a distal osteotomy combined with a correction osteotomy based on the proximal phalanx can be performed in HV in the moderate and severe categories (> 30 degrees / > 15 degrees). However, if the distortion is severe enough to cause joint subluxation, soft tissue repair, and

proximal metatarsal osteotomy can be performed. The goal of this basal portion osteotomy is to narrow the intermetatarsal angle.² The Hallux valgus in the elderly should be addressed with footwear modification, and if it fails, arthroplasty excision can be performed. In Keller's procedure, the proximal phalanx and the bun protrusion are removed first. Previously, this type of surgery was the most widely used, but the recurrence rate was high, and complications such as loss of control of the movement of the big toe, other metatarsals having excessive loads, metatarsalgia, and other cosmetic reasons could arise.²

Complications

Undercorrection, recurrence, overcorrection (hallux varus), transfer metatarsalgia, nonunion, malunion, avascular necrosis, arthritis, hardware removal, nerve injury, and subsequently patient unhappiness are some of the most frequently reported complications following HV reconstruction.^{23,25} These complications are likely to occur in 10% - 55% of cases.²⁶ These complications can be asymptomatic at times, but they frequently result in a painful and/or dysfunctional first metatarsal. After HV surgery, a recent systematic analysis of the literature found a combined rate of postoperative patient dissatisfaction of 10.6% and a residual pain level of 1.5% in the first metatarsophalangeal (MP).²⁷ In comparison to distal methods (Chevron: 5.56%), proximal operations

(closing base wedge osteotomy: 8.82%; Lapidus: 8.19%) have higher rates of revision surgery.²⁸ Revision surgery can be necessary if conservative methods do not relieve pain. In certain circumstances, revision of the first ray alone may result in a satisfactory outcome; however, in others, surgery on the lesser rays or both together may be required to obtain a mechanically sound forefoot.²⁹

Summary Points

1. Hallux valgus (HV) is a complex disorder with a variety of deformities varying in severity, implying that numerous variables are involved. Although the exact etiology of HV is unknown, it is believed that both intrinsic and extrinsic factors may play a role in its development.
2. Physical examination and imaging assessment in a weight-bearing position are required for the diagnosis of HV.
3. Imaging assessment should describe the status of MTP, mobility, presence of arthritis, and radiographic parameters such as hallux valgus and intermetatarsal angles.
4. Asymptomatic HV does not necessitate surgical correction.
5. The first-line treatment for symptomatic HV is conservative; including shoe modification, orthotic use, and night splinting which unfortunately will not reverse the deformity.
6. If conservative treatment fails, surgical correction is recommended to improve functional outcomes.

References

1. Easley ME, Trnka H-J. Current concepts review: hallux valgus part 1: pathomechanics, clinical assessment, and nonoperative management. *Foot Ankle Int* [Internet]. 2007;28(5):654–9. Available from: <http://dx.doi.org/10.3113/FAI.2019.0654>
2. Solomon L, Warwick D, Nayagam S. *Apley and Solomon's concise system of orthopedics and trauma*. CRC Press; 2014.
3. Piqué-Vidal C, Solé MT, Antich J. Hallux valgus inheritance: pedigree research in 350 patients with bunion deformity. *J Foot Ankle Surg* [Internet]. 2007;46(3):149–54. Available from: <http://dx.doi.org/10.1053/j.jfas.2006.10.011>.
4. Nix S, Smith M, Vicenzino B. Prevalence of hallux valgus in the general population: a systematic review and meta-analysis. *J Foot Ankle Res* [Internet]. 2010;3(1):21. Available from: <http://dx.doi.org/10.1186/1757-1146-3-21>.
5. Kuhn J, Alvi F. Hallux Valgus. 2022 Sep 29 [cited 2023 Jan 21]; Available from: <https://www.ncbi.nlm.nih.gov/books/NBK553092/>
6. Hardy RH, Clapham JCR. Observations on hallux valgus; based on a controlled series. *J Bone Joint Surg Br* [Internet]. 1951;33-B(3):376–91. Available from: <http://dx.doi.org/10.1302/0301-620X.33B3.376>.
7. Barnicot NA, Hardy RH. The position of the hallux in West Africans. *J Anat*. 1955;89(3):355–61.
8. Soemarmo DS, Rahmasari F, Kamal AF, Cahayadi SD, Herqutanto. Hallux valgus among sales promotion women wearing high heels in a department store. *J Orthop Surg (Hong Kong)* [Internet]. 2019;27(1):2309499019828456. Available from: <http://dx.doi.org/10.1177/2309499019828456>
9. Ferreyra M, Núñez-Samper M, Viladot R, Ruiz J, Isidro A, Ibañez L. What do we know about hallux valgus pathogenesis?: Review of the different theories. *J Foot Ankle* [Internet]. 2020;14(3):223–30. Available from: <http://dx.doi.org/10.30795/jfootankle.2020.v14.1202>
10. Glasoe WM, Nuckley DJ, Ludewig PM. Hallux valgus and the first metatarsal arch segment: a theoretical biomechanical perspective. *Phys Ther* [Internet]. 2010;90(1):110–20. Available from: <http://dx.doi.org/10.2522/ptj.20080298>
11. Yu G, Fan Y, Fan Y, Li R, Liu Y, Antonijevic D, et al. The role of footwear in the pathogenesis of hallux Valgus: A proof-of-concept finite element analysis in recent humans and Homo naledi. *Front Bioeng Biotechnol* [Internet]. 2020;8:648. Available from: <http://dx.doi.org/10.3389/fbioe.2020.00648>.
12. Hallux Valgus: Pathogenesis and clinical findings | Calgary Guide [Internet]. [cited 2023 Jan 21]. Available from: <https://calgaryguide.ucalgary.ca/hallux-valgus-pathogenesis-and-clinical-findings/>
13. Steadman J, Barg A, Saltzman CL. *First Metatarsal Rotation in Hallux Valgus Deformity*. Vol. 42, *Foot and Ankle International*. SAGE Publications Inc.; 2021. p. 510–22.
14. Stephens MMC, Stephens MM, Ortho C. Pathogenesis of hallux valgus. Vol. 1, *EUR J FOOT ANKLE SURG*. 1994.
15. Wheeler Haines R, McDougall A. *THE ANATOMY OF HALLUX VALGUS*. 2021
16. Choa R, Sharp R, Mahtani KR. Hallux valgus. *BMJ*. 2010;341. Available from: <https://doi.org/10.1136/bmj.c5130>
17. Leigheb M, Baricich A, Alberto Grassi F. Influence of hallux valgus management on Quality of Life Wrist trauma View project Multidisciplinary Rehabilitation and Nutritional interventions in Osteoporotic Hip Fracture View project [Internet]. 2012. Available from: <https://www.researchgate.net/publication/267221635>
18. Kakwani M, Kakwani R. Current concepts review of hallux valgus. Vol. 8, *Journal of Arthroscopy and Joint Surgery*. Reed Elsevier India Pvt. Ltd.; 2021. p. 222–30. Available from: <http://dx.doi.org/10.1016/j.jajs.2021.04.006>
19. Hecht PJ, Lin TJ. Hallux valgus. Vol. 98, *Medical Clinics of North America*. 2014. p. 227–32. Available from: <http://dx.doi.org/10.1016/j.mcna.2013.10.007>
20. Nakagawa R, Yamaguchi S, Kimura S, Sadamasu A,

- Yamamoto Y, Muramatsu Y, et al. Efficacy of foot orthoses as nonoperative treatment for hallux valgus: A 2-year follow-up study. *Journal of Orthopaedic Science*. 2019 May 1;24(3):526–31. Available from: <http://dx.doi.org/10.1016/j.jos.2018.11.003>
21. Reina M, Lafuente G, Munuera PV. Effect of custom-made foot orthoses in female hallux valgus after one-year follow up. *Prosthet Orthot Int*. 2013 Apr;37(2):113–9. Available from: <http://dx.doi.org/10.1177/0309364612447097>
 22. Torkki M, Malmivaara A, Seitsalo S, Hoikka V, Laippala P, Paavolainen P. Hallux valgus: Immediate operation versus 1 year of waiting with or without orthoses - A randomized controlled trial of 209 patients. *Acta Orthop Scand*. 2003 Apr;74(2):209–15. Available from: <http://dx.doi.org/10.1001/jama.285.19.2474>
 23. Monteagudo M, Martínez-de-Albornoz P. Management of Complications After Hallux Valgus Reconstruction. *Foot and Ankle Clinics*. W.B. Saunders; 2020;25(1):151–67. Available from: <http://dx.doi.org/10.1016/j.fcl.2019.10.011>
 24. Fraissler L, Konrads C, Hoberg M, Rudert M, Walcher M. Treatment of hallux valgus deformity. *EFORT Open Rev*. 2016 Aug 1;1(8):295–302. Available from: <http://dx.doi.org/10.1302/2058-5241.1.000005>
 25. Baravarian B, Ben-Ad R. Revision hallux valgus. Causes and correction options. *Clinics in Podiatric Medicine and Surgery*. W.B. Saunders; 2014;31(2):291–8. Available from: <http://dx.doi.org/10.1016/j.cpm.2013.12.010>
 26. Lee KT, Park YU, Jegal H, Lee TH. Deceptions in hallux valgus. What to look for to limit failures. *Foot and Ankle Clinics*. W.B. Saunders; 2014;19(3):361–70. Available from: <http://dx.doi.org/10.1016/j.fcl.2014.06.003>
 27. Barg A, Harmer JR, Presson AP, Zhang C, Lackey M, Saltzman CL. Unfavorable outcomes following surgical treatment of hallux valgus deformity: A systematic literature review. *Journal of Bone and Joint Surgery - American Volume*. 2018;100(18):1563–73. Available from: <http://dx.doi.org/10.2106/jbjs.17.00975>
 28. Lagaay PM, Hamilton GA, Ford LA, Williams ME, Rush SM, Schubert JM. Rates of Revision Surgery Using Chevron-Austin Osteotomy, Lapidus Arthrodesis, and Closing Base Wedge Osteotomy for Correction of Hallux Valgus Deformity. *Journal of Foot and Ankle Surgery*. 2008 Jul;47(4):267–72. Available from: <http://dx.doi.org/10.1053/j.jfas.2008.03.002>
 29. Hernández-Castillejo LE, Martínez Vizcaíno V, Garrido-Miguel M, Caverro-Redondo I, Pozuelo-Carrascosa DP, Álvarez-Bueno C. Effectiveness of hallux valgus surgery on patient quality of life: a systematic review and meta-analysis. *Acta Orthop*. 2020 Jul 3;91(4):450–6. Available from: <http://dx.doi.org/10.1080/17453674.2020.1764193>