Clinical Research

Early debridement improves outcome in managing ankle tuberculosis: a systematic review

Ignatius Angga Rusdianto,[1] Fidia Tania,[2] Belinda Azhari Siswanto,[3] Astuti Pitarini[4]

[1,2,3] Department of Orthopaedic Surgery, St. Carolus Bone and Joint Centre, Jakarta, Indonesia

ABSTRACT

Introduction: Extrapulmonary tuberculosis (EPTB) accounting for 10% of all cases and the involvement of the musculoskeletal system was only 3%, in which the spinal TB is the most common form. The incidence of ankle TB was found to be less than 1% of all musculoskeletal TB and often misdiagnosed. In Indonesia, the prevalence of TB is 660 from 100,000 people. There is no known data for EPTB, including musculoskeletal TB. The diagnosis of tuberculosis infection in a joint is difficult. Untreated ankle TB and diagnostic delay may result in local cartilage destruction and functional disability, leading to a poorer prognosis. This systematic review aims to find out if early surgical treatment of ankle TB affects the outcomes and the importance of laboratory tests of ankle TB. Our hypothesis predicts better outcomes with earlier surgical treatment for ankle TB.

Methods: EBSCO, Proquest, Pubmed, ScienceDirect, and Google Scholar were searched using the terms "ankle", "tuberculosis", "arthroscopy", "debridement" and "open". After identification and review of the included study publications, these variables were extracted from the studies: authors, publication year, place, age, delayed onset of surgery, clinical findings, laboratory and diagnostic findings, surgery technique, tuberculosis drug, and outcome.The inclusion criteria included studies on arthroscopic or open debridement surgical management of ankle tuberculosis, English-language studies, and articles published between 2004-2019. The exclusion criteria included studies that perform arthrodesis and patients with multi-drug resistance tuberculosis.

Results: After an initial search of 59 studies, 19 duplicates were removed and the final remaining 11 studies were used for inclusion (6 case-control studies, 4 case series, and 1 cohort). The studies considered were all published between 2010 and 2019. In total, there are 103 patients with a mean age of 43.8 years (7-90) treated for ankle TB with arthroscopy debridement, open debridement, and synovectomy. The mean delayed time of surgery is 10.9 months (1-80) and outcomes were evaluated over a mean of 35.5 months postoperatively (1.5-260). All patients were treated with Rifampicin, Isoniazid, Pyrazinamide, and Ethambutol (RIPE) with mean of treatment of 10 months (ranges from 4-21). No patients were lost to follow up.

Conclusion: Early debridement is recommended to improve outcomes in managing ankle TB.

ABSTRAK

Pendahuluan: *Tuberkulosis (TB) ekstra paru berkisar 10% dari semua kasus tuberkulosis. Keterlibatan TB pada sistem muskuloskeletal yaitu sebanyak 3% dengan predileksi di daerah tulang belakang. Insiden TB pergelangan kaki berkisar kurang dari 1% dari semua TB muskuloskeletal dan seringkali tidak terdiagnosis. Di Indonesia, belum ada data mengenai TB muskuloskeletal namun untuk prevalensi TB paru adalah 660 pada 100.000 orang. Diagnosis pada infeksi tuberkulosis pada persendian memang lebih sulit untuk ditegakkan. TB pergelangan kaki yang terlambat dalam diagnosa serta yang tidak tertangani akan menyebabkan kerusakan tulang rawan dan mengakibatkan gangguan fungsi. Tujuan dari tinjauan sistematis ini adalah untuk mengetahui apakah pengobatan bedah dini pada TB pergelangan kaki akan mempengaruhi fungsi dan klinis pasien. Hipotesis kami memprediksi hasil yang memuaskan dalam debridemen lebih dini untuk TB pergelangan kaki.*

Metode: *Kata kunci* "ankle", "tuberculosis", "arthroscopy", "debridement" *dan* "open" *digunakan untuk pencarian artikel. Mesin pencarian yang digunakan adalah EBSCO, Proquest, Pubmed, Science Direct, dan Google Scholar. Setelah dilakukan identifikasi dan peninjauan studi, variabel-variabel berikut diambil dan dianalisa, yaitu; penulis, tahun publikasi, tempat, usia, onset operasi, temuan klinis, temuan laboratorium dan diagnostik, teknik operasi, obat tuberkulosis, dan hasil. Kriteria inklusi yang digunakan adalah tata laksana debridemen pada tuberkulosis pergelangan kaki, artikel yang ditulis dalam bahasa Inggris, dan artikel yang diterbitkan antara tahun 2004-2019. Sedangkan untuk kriteria eksklusi adalah studi yang melakukan artrodesis dan pasien dengan TB yang resistan terhadap berbagai obat.*

Hasil: *Pada pencarian awal, didapatkan 59 studi yang kemudian ditemukan 19 duplikat studi. Penulis menggunakan 9 studi untuk ditelaah (6 studi kasus-kontrol, 2 kasus serial dan 1 kohort). Studi yang ditelaah diterbitkan pada tahun 2004 hingga 2019. Secara total, 72 pasien dengan usia rata-rata 45,1 tahun (7-90) dirawat untuk TB pergelangan kaki dengan debridemen artroskopi, debridemen terbuka, dan sinovektomi. Waktu rata-rata penundaan operasi adalah 13,1 bulan (1-80) dan hasil dievaluasi selama rata-rata 36,3 bulan pasca operasi (1,5-260). Semua pasien diobati dengan Rifampisin, Isoniazid, Pyrazinamide, dan Ethambutol dengan rata-rata pengobatan 10 bulan (kisaran 4-21). Tidak ada pasien yang hilang dalam pemantauan.*

Kesimpulan: *Debridemen dini direkomendasikan untuk memberikan hasil yang baik dalam mengelola TB pergelangan kaki.*

Keywords: Tuberculosis, Extrapulmonary, Ankle, Debridement, Systematic Review
https://doi.org/ 10.31282/joti.v3n1.52

Corresponding author : Ignatius Angga Rusdianto, MD. angga.rusdianto@hotmail.com

INTRODUCTION

Pulmonary tuberculosis (TB) is the most common form of TB worldwide. One-third of the world's population has been infected with *Mycobacterium tuberculosis*. Furthermore, extrapulmonary TB (EPTB) accounting for 10% of all cases and the involvement of the musculoskeletal system was only 3%, in which the spinal TB is the most common form.[1] The incidence of ankle TB was found to be less than 1% of all musculoskeletal TB and often misdiagnosed.[2]

In Indonesia, the prevalence of TB is 660 from 100,000 people. There is no known data for EPTB, including musculoskeletal TB. The most difficult to diagnose EPTB is ankle TB. The classic systemic symptoms of TB such as fever, night sweats, and weight loss are frequently absent. The clinical history and symptoms are important and generally raise suspicion of ankle TB. Ankle TB often develops insidiously without early classic signs.

The diagnosis of tuberculosis infection in a joint is quite difficult and misdiagnosis is common due to its atypical clinical presentation, wide use of antibiotics, and lack of specificity in diagnosis.[3] Ankle TB may have poor prognosis if left untreated and diagnostic delay has the potential to make more local destruction and functional disability.

The conservative treatment remains important but some situations demand surgical intervention[4]. This systematic review aims to find out if early surgery treatment of ankle TB affects the outcomes. In addition, we also evaluate the importance of laboratory tests of ankle TB. We hypothesized that better outcomes, clinically and functionally, will be achieved if the surgery performs earlier.

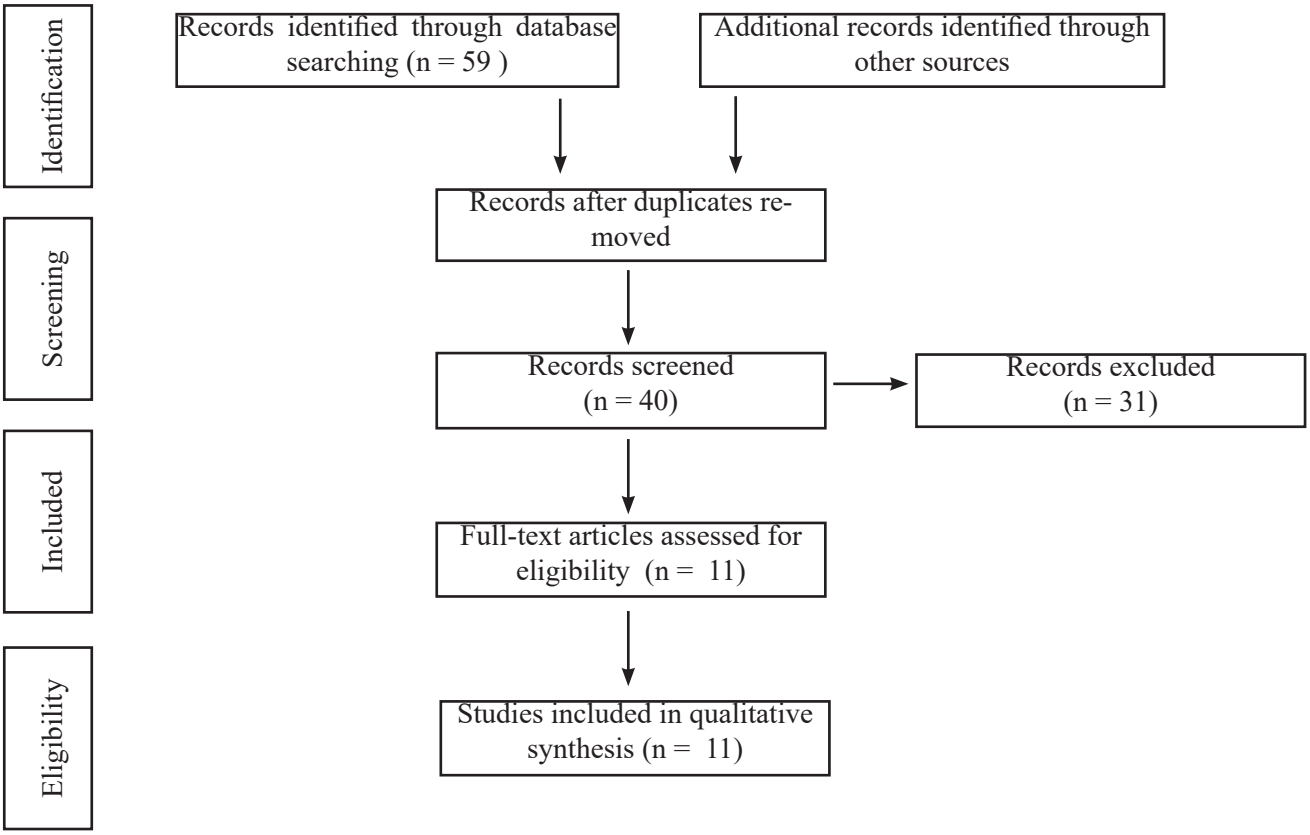

Figure 1. Flow Diagram of Searching

METHODS

Search Strategy

The online databases of EBSCO, Proquest, Pubmed, Science Direct, and Google Scholar were searched for the search-terms of "ankle", "tuberculosis", "arthroscopy", "debridement" and "open". The titles, abstracts, and full-text articles were screened by the 4 authors. The references of other studies were also searched from other sources to expand additional articles that may have not

included in the initial search strategy.

The inclusion criteria included studies on arthroscopic or open debridement surgical management of ankle tuberculosis, English-language studies, and articles published during 2010-2019. The exclusion criteria included studies that perform arthrodesis and patients with multi-drug resistance tuberculosis.

After identification and review of the included studies, these following variables were extracted from the studies: authors, publication year, place, age, delayed onset of surgery, clinical findings, laboratory and diagnostic findings, surgery technique, tuberculosis drug, and outcome. These variables were later composed in a table to find out if early surgery treatment of ankle TB affects the outcome.

RESULTS

After an initial search of 59 studies, 19 duplicates were removed, and the final remaining 11 studies were used for inclusion.

Study Characteristics

We found 6 case-control studies, 2 case series, and 1 cohort examining debridement treatment of ankle TB. One study was conducted in America, 1 study in the UK, 1 study in Finland, 2 studies in Taiwan, 1 study in India, 1 study in China, and 1 study in Japan. These studies were published between 2004 and 2019. In total, there are 103 patients with a mean age of 43.8 years (7-90) treated for ankle TB with arthroscopy debridement, open debridement, and synovectomy. The mean delayed time of surgery is 10.9 months (1-80) and the outcomes were evaluated over a mean of 35.5 months postoperatively (1.5-260). All patients were treated with Rifampicin, Isoniazid, Pyrazinamide, and Ethambutol (RIPE) with a mean of treatment of 10 months (ranges from 4-21). No patients were lost to follow up.

Table 1. Participant Demographic Data in TB Ankle studies

Study/Year	Place	Study Design, Level of Evidence	Sample Size	Age (Years)*	Time from Symptom to Surgery (Months)
Pereira *et al./* 2017[2]	India	Case report, level IV	1	30	12
Shams *et al./* 2019[3]	America	Case report, level IV	1	53	8
Brew *et al./*2010[4]	UK	Case report, level IV	1	41	7
Titov *et al./*2004[5]	Finland	Case report, level IV	1	72	NR
Lin *et al./*2009[6]	Taiwan	Case report, level V	2	54 (43-65)	6 (6-12)
Duan *et al./*2019[7]	China	Case series, level IV	15	37,5 (8-70)	16 (3-36)
Inoue *et al./*2004 [8]	Japan	Case report, level IV	2	27,5 (17-38)	5,5 (3-8)
Chen *et al./*2013 [9]	Taiwan	Case series, level IV	15	57 (9-90)	7.9 (1-24)
Gursu *et al./*2014[10]	Turkey	Cohort Retrospective, level IV	40	34,4 (7-85)	26.4 (1–180)
Tang *et al./*2007[11]	China	Case Series, level IV	10	32 (28-56)	13 (8-23)
Fattouh *et al./*2012[12]	Egypt	Case series, level IV	4	48.5 (42-55)	4.5 (3-6)
Samuel *et al./*2011[13]	India	Cohort Retrospective, level IV	11	38 (19-73)	12 (1-36)
Total/mean across studies		Level IV: 11 Level V: 1	103	43.8 (7-90)	10.9 (1-180)

Abbreviation: NR (Not Reported); *Age and Follow-up are reported as mean (ranges) unless the cases with one sample size

Surgical Indications

The pillar treatment remains appropriate multidrug regiment antibiotics, but some situations demanded surgical interventions. The decision to proceed with the surgical intervention was based on a combination of clinical, laboratory, and imaging parameters. Limited active and passive range of motion (ROM), late-disease presentation with associated discharging sinus, or non-healing ulcer were the indications for surgery for all of the studies. The laboratory findings of the studies included positive

tuberculin skin tests and elevated ESR, CRP, and WBC. Diagnostic imaging used inconsistently across all the studies including plain radiographs, computed tomography, and magnetic resonance imaging. Bone culture was performed in all ofthe studies. Advanced cases that presenting narrowed or collapsed joint space and severe bone destruction could undergo arthrodesis, which is not included in this systematic review. Surgical intervention helped to confirm the definitive and early diagnosis to achieve a good outcome and preventing deformity.

Table 2. Radiographic Indications for Surgical Treatment of TB Ankle

Study/year	History of Lung TB	X-ray	CT SCAN	MRI
Pereira *et al./* 2017[2]	(-)	normal	NR	Lesion over tibiotalar joint, joint effusion and cartilage destruction of ankle joint
Shams *et al./* 2019[3]	(-)	Stage II	NR	NR
Brew *et al./*2010[4]	(-)	Stage III	Changes consistent with atypical infection	Osteomyelitis centered over talonavicular joint with gross thickening of synovium surrounding ankle mortise
Titov *et al./*2004[5]	NR	NR	NR	NR
Lin *et al./*2009[6]	(-)	Stage I	NR	Hypertrophic synovitis with periarticular soft tissue swelling and subchondral erosion with bone marrow edema in left ankle and subtalar joint
	(-)	Stage IV	NR	Severe hypertrophic synovitis with subchondral erosion and bone marrow edema in right ankle
Duan *et al./*2019[7]	(+) n = 5 (-) n = 10	Stage I (n = 1) Stage II (n = 14)	NR	Effusion in the ankle articular cavity, bone edema of distal radius and talus
Inoue *et al./*2004 [8]	(-)	Stage III	NR	NR
	NR	Stage III	NR	NR
Chen *et al./* 2013 [9]	(+) n = 7 (-) n = 8	Stage I (n = 5) Stage II (n = 10)	NR	NR
Gursu *et al./*2014[10]	NR	Stage 1 (n = 27) Stage II (n = 13)	NR	NR
Tang *et al./*2007[11]	(+) n=5 (-) n =5	Stage II (n=10)	NR	Sclerosis, central and peripheral erosions
Fattouh *et al./*2012[12]	(-) n=4	Stage II (n=4)	NR	NR
Samuel *et al./*2011[13]	(+) n=2 (-) n=9	Stage 1 (n=5) Stage II (n=6)	Lytic lesion	NR

Abbreviation: NR (Not reported)

Table 3. Laboratory and Pathology Findings for Surgical Treatment of TB Ankle

Study/Year	Abnormal Lab Finding	Histology Finding	Culture
Pereira et al./ 2017[2]	ESR 30 mm/hour	NR	(+) bone
Shams *et al./* 2019[3]	WBC 13,000 cells/mm3	Necrotizing and non-necrotizing granuloma	(+) bone
Brew *et al./*2010[4]	ESR elevated	Abundant epithelioid granulomas and large area of caseating necrosis	(+) bone
Titov *et al./*2004[5]	NR	NR	(+) bone
Lin *et al./*2009[6]	ESR 44 mm/hour	NR	(+) bone
	44 mm/hour	Consistent with TB	(+) bone
Duan *et al./*2019[7]	Elevated ESR and CRP	NR	(+) (n:13) (-) (n:2)
Inoue *et al./*2004 [8]	ESR 64 mm/hour, CRP 5.5 mg/dL	(+)	(+) bone
	ESR 36 mm/hour	NR	(+) bone
Chen *et al./*2013 [9]	WBC 8,400/mm3, ESR 57.4, CRP > 5 mg/dL	Granulomatous lesion	(+) bone
Gursu *et al./*2014[10]	ESR 41.3 mm/hour (22-101), CRP mg/dL 31.7 (12-88)	Extensive necrosis, caseification	(+) Lowenstein-Jensen agar
Tang *et al./*2007[11]	Elevated ESR and C-reactive protein	NR	(+) bone
Fattouh *et al./*2012[12]	ESR 100 mm, CRP (++)	Granulomas and caseating necrosis	(+) Lowenstein-Jensen
Samuel *et al./*2011[13]	NR	NR	(+) bone

Abbreviation: NR (Not Reported), ESR (Erythrocyte Sedimentation Rate), CRP (C-Reactive Protein)

Table 4. Treatment of TB Ankle

Study/year	Surgical Approach	Post-Operative Treatment	TB Drug Treatment
Pereira *et al./* 2017[2]	Arthroscopy debridement	Non-weight bearing for 1 month and ankle joint mobilization	RIPE 9 months
Shams *et al./* 2019[3]	Open debridement	-	RIPE + Levofloxacin 500mg 12 months
Brew *et al./*2010[4]	Open debridement	Boot support for a few months	Rifampicin, ethambutol and pyridoxine
Titov *et al./*2004[5]	Arthroscopy followed by open debridement	-	Gentamicin, Isoniazid, Rifampicin 1 month Ethambutol, Isoniazid, Pyrazinamide 3 months
Lin e*t al./*2009[6]	Arthroscopy debridement and synovectomy	Partial weight bearing for 4 months	RIPE 6 months
	Arthroscopy debridement	-	RIPE 4 months

Duan *et al./*2019[7]	Arthroscopy debridement	High protein diet, Weight-bearing exercise in 2 weeks post-operation	RIPE 3 months, Ibuprofen, Rifampicin and Pyrazinamide for another 3 months, Isoniazid and Rifampicin 12 months
Inoue *et al./*2004 [8]	Open debridement	Non-weight bearing for 6 months	RIE for 1 year followed by RI for 4 months and I for 5 months
	Open debridement and Sinus Trans Resection	Non-weight bearing for 2,5 months	RIE for 12 months
Chen *et al./*2013[9]	Synovectomy	Distraction apparatus	RIPE for 2 months followed by RIE for 10 months
Gursu *et al./*2014[10]	Open debridement	-	Mean RIPE 8.2 (3-17)
Tang et al./2007[11]	Arthroscopy debridement	-	RIPE before and after surgery
Fattouh *et al./*2012[12]	Synovectomy	Non-weight bearing for 5 weeks	RIPE 6 months
Samuel *et al./*2011[13]	Synovectomy	-	RIPE 10 months

Table 5. Clinical Outcomes after Treatment of TB Ankle

Study/Year	Subjective Clinical Outcome	Clinical Outcome Score	Follow-Up (Months)
Pereira *et al./* 2017[2]	Almost full ROM with terminal restriction of dorsiflexion. Joint pain on weight-bearing for long duration	-	24
Shams *et al./* 2019[3]	Extensive ankle joint destruction with loss of motion	-	2
Brew *et al./*2010[4]	Full ROM		12
Titov *et al./*2004[5]	Insufficient	-	1,5
Lin *et al./*2009[6]	Pain/ weight-bearing/ Full ROM		4
	Pain while walking		12
Duan *et al./*2019[7]	Full ROM	VAS score 1.0 ± 0.5 AOFAS score 85 ± 7	24
Inoue *et al./*2004[8]	Full ROM	-	96
	Full ROM	-	144
Chen *et al./*2013[9]	8 full ROM, 6 not full ROM, 1 talar bone collapse	Rating scale of Teeny and Wiss 88.7 (60-92)	73.1 (30-260)
Gursu *et al./*2014[10]	No recurrence of infection	-	21.7 (8-30)
Tang *et al./*2007[11]	Full ROM	AOFAS score 66 (58-82)	23.2(6-46)
Fattouh *et al./*2012[12]	No clinical manifestation	-	-
Samuel *et al./*2011[13]	No infection	-	24 (9-81)

DISCUSSION

The aim of this systematic review is to find out if earlier surgical treatment will bring better outcome. The results have shown better outcomes achieved in a shorter delay of treatment, with the average of 11.5 (6-26.4) months, compared to the poorer outcomes with the average of delay of 14 (8-24) months. Each of the studies was treated by one surgeon. There are no data about hemorrhage and duration of operation in the studies.

Diagnosis for ankle TB is difficult as it is usually detected in the late stage. The most common symptoms include pain, swelling, and stiffness, while swelling with fullness around malleoli and achilles tendon insertion, plantar flexion of ankle joint are the important signs of ankle-foot TB. Classical symptoms such as fever, night sweats, and weight loss may be absent, and the history of lung TB may not be seen in most cases. Only Duan *et al*. and Chen *et al*. reported positive histories of lung TB and Inoue *et al*. reported fever in their case report. Therefore, we have to be aware of this condition because the diagnosis can often be confusing, delayed the treatment, and increased the risks of secondary infections. Pereira *et al*. suggested early biopsy and PCR-GeneXpert in addition to the routine investigation.

Almost all patients significantly improved after adjuvant surgery. More specifically, most patients were asymptomatic with full ROM and no recurrence of infection. Clinical outcome score only reported by Duan *et al*. and Chen *et al*., where all patients had significant VAS and AOFAS scores improvement. Whilst in imaging outcome, Tang *et al*. reported a radiographic fusion in 14.5 weeks.

Despite that, we found eight cases with unsatisfactory outcomes requiring arthrodesis and one case with no recurrence of TB but the patient felt pain while walking due to severe secondary osteoarthritis. In these cases, the delayed operation ranged from 8-24 months. Pereira *et al*. proposed arthrodesis following the destruction of the articular cartilage. The patient showed no recurrence of infection but there was a restriction of the ankle dorsiflexion. Shams *et al*. reported similar cases with diabetes mellitus as the underlying disease which needed a follow-up arthrodesis after the ankle debridement owing to extensive ankle joint destruction with loss of motion. Titov *et al*. reported a case with the primary result after arthroscopic debridement was judged as insufficient and an open pantalar fusion with bone graft was done in the same session. Another case by Duan *et al*. reported a fair outcome. The patient was reported with no evidence of recurrence but felt pain while walking due to severe secondary arthritis. Chen *et al*. reported four patients treated with not full ROM and one talar bone collapse even though the ankle TB was under control. They reported that the result was much better in the earlier stages of ankle TB before extensive joint destruction and bone loss. The ankle x-ray for these poor outcome cases varied from stage I to IV. Furthermore, radiographs of the infected joint might reveal narrowing or osteoporosis but the CT or MRI provided a more specific of localizing and evaluating bone destruction and soft tissue involvement. Almost all cases had shown positive bone culture three weeks post-biopsy, and only Gursu *et al*. using Lowenstein-Jensen agar culture for evaluation. Synovial fluid aspiration is not always positive for Mycobacterium TB. Shams *et al*. described that acid-fast bacilli (AFB) are not frequently seen in synovial fluid, as the infection is tissue-based. AFB stains of synovial fluid are positive in only 20% of their cases. They said that the positive culture would be higher in the tissue, such as infected synovial capsule or bone culture, like in our systematic review results. Chemotherapy is still the main therapy for musculoskeletal tuberculosis, whilst debridement is recommended as an adjunct therapy in more severe clinical and radiologic findings, this study showed that chemotherapy in combination with surgery delivered satisfying results.

The postoperative rehabilitation also plays an important role. The average duration of non-weight bearing in the mentioned studies was 2.5 (ranges 0.5-6 months). However, Lin *et al*. allowed partial weight-bearing for 4 months post-operation and Duan *et al*. gave weight-bearing exercise in 2 weeks post-operation. Duan *et al*. also suggested a high protein diet as support for the post-operation of ankle TB.

From a methodologic point of view, limitations of this systematic review include lack of evidence from high-quality randomized controlled trials, lack of control groups, heterogeneous outcomes, and small, limited sample sizes. However, larger sample sizes, with long-term follow-up data, have not been reported.

CONCLUSION

Ankle tuberculosis should be a part of differential diag-

nosis in patients presenting pain, swelling, and limited of ROM in the ankle, especially in the setting of high TB epidemiology and underlying immunosuppressive comorbid conditions.

We recommend early debridement to improve outcomes in managing ankle TB. The combination of chemotherapy, surgery, and non-weight bearing is currently an effective choice of treatment for ankle tuberculosis. Early diagnosis and treatment give more satisfying outcomes with no recurrences.

Acknowledgement

The authors report no acknowledgment in this work

REFERENCES

1. Alper Sener, Erdem H. *Extrapulmonary Tuberculosis*. Springer; 2019. https://doi.org/10.1007/978-3-030-04744-3
2. Pereira J, Anoop S, Pettah GJ. A Case of Chronic Inflammation of the Ankle Joint with Subtle Signs of Inflammation: A Rare Presentation of Tuberculosis Ankle. *J Orthop Case Rep*. 2017;7(1):87. doi:10.13107/jocr.2250-0685.702
3. Shams F, Asnis D, Lombardi C, Segal-Maurer S. A Report of Two Cases of Tuberculous Arthritis of the Ankle. *J Foot Ankle Surg*. 2009;48(4):452-456. doi:10.1053/j.jfas.2009.04.004
4. Brew CJ, Rao V, Shanker J. Tuberculosis infection of the talonavicular joint. *The Foot*. 2010;20(4):146-148. doi:10.1016/j.foot.2010.08.001
5. Titov AG, Nakonechniy GD, Santavirta S, Serdobintzev MS, Mazurenko SI, Konttinen YT. Arthroscopic operations in joint tuberculosis. *Knee Amst*. 2004;11(1):57-62. doi:http://dx.doi.org/10.1016/S0968-0160(03)00035-8
6. Lin R-C, Lu K-H, Lue K-H. Adjuvant Arthroscopy for Ankle Tuberculosis: A Report of Two Cases. *Foot Ankle Int*. 2009;30(1):74-79. doi:10.3113/FAI.2009.0074
7. Duan X, Yang L. Arthroscopic management for early-stage tuberculosis of the ankle. *J Orthop Surg*. 2019;14(1):25. doi:10.1186/s13018-018-1048-y
8. Inoue S, Matsumoto S, Iwamatsu Y, Satomura M. Ankle tuberculosis: a report of four cases in a Japanese hospital. *J Orthop Sci*. 2004;9(4):392-398. doi:10.1007/s00776-004-0792-5
9. Chen S-H, Lee C-H, Wong T, Feng H-S. Long-term retrospective analysis of surgical treatment for irretrievable tuberculosis of the ankle. *Foot Ankle Int*. 2013;34(3):372-379. doi:10.1177/1071100712464955
10. Gursu S, Yildirim T, Ucpinar H, et al. Long-term Follow-up Results of Foot and Ankle Tuberculosis in Turkey. *J Foot Ankle Surg*. 2014;53(5):557-561. doi:10.1053/j.jfas.2014.04.012
11. Tang K-L, Li Q-H, Chen G-X, Guo L, Dai G, Yang L. Arthroscopically Assisted Ankle Fusion in Patients With End-Stage Tuberculosis. *Arthrosc J Arthrosc Relat Surg*. 2007;(9):919.
12. Fattouh M, Hafez AR, Ahmed ZH. Diagnosis and Treatment of Ankle Tuberculosis in Sohag University Hospital. :5.
13. Samuel S, Boopalan PRJVC, Alexander M, Ismavel R, Varghese VD, Mathai T. Tuberculosis of and around the Ankle. *J Foot Ankle Surg*. 2011;50(4):466-472. doi:10.1053/j.jfas.2011.04.002