

## Case Report

**Bony resection and suture anchor repair in Haglund deformity with insertional achilles tendinopathy**Ihsan Oesman<sup>1</sup> Rizki Hidayat<sup>2</sup>

<sup>1,2</sup>Department of Orthopaedic & Traumatology, Faculty of Medicine, Universitas Indonesia,  
Cipto Mangunkusumo Hospital, Jakarta, Indonesia

**ABSTRACT**

**Introduction:** Achilles tendinopathy is a combination of pain, swelling, and impaired performance due to Achilles tendon condition. Chronic case of this disease mostly failed with conservative treatment, however, operative approach will improve the function of the Achilles tendon.

**Methods:** We report an elderly patient with Achilles tendinopathy, who clinically had Haglund deformity and insertional Achilles tendinopathy. The patient had failed non-operative treatment and undergone surgery with calcaneal osteotomy and Achilles tendon repair using suture anchor.

**Results:** The primary goal of the surgery in Achilles tendinopathy was correction of the deformity and thorough debridement at the site of inflammation. The Haglund deformity can be corrected with posterior calcaneal osteotomy and calcification at the Achilles insertion must be removed. Because the site of calcification was at the distal end of the Achilles tendon, suture anchor repair was the best choice to get stable fixation of the tendon.

**Conclusion :** Bony resection for Haglund deformity and debridement and suture anchor repair for the insertional Achilles tendinopathy are effective surgical treatments for Achilles tendinopathy.

**ABSTRAK**

**Pendahuluan:** Achilles tendinopathy merupakan sindrom kombinasi dari nyeri, pembengkakan, dan gangguan fungsional akibat kondisi tendon Achilles. Sebagian besar kasus kronis penyakit ini gagal ditangani dengan pengobatan konservatif, oleh karenanya pendekatan operatif merupakan salah satu pilihan tatalaksana untuk memperbaiki fungsi tendon Achilles.

**Metode:** Kami melaporkan pasien lansia penyandang Achilles tendinopati yang secara klinis memiliki kelainan deformitas Haglund dan tendinopati Achilles. Pasien mengalami kegagalan dalam perawatan non-operatif dan menjalani tindakan operasi berupa *osteotomy calcaneus* dan perbaikan tendon dengan *suture anchor*.

**Hasil:** Tujuan utama operasi pada tendinopati Achilles adalah koreksi deformitas dan debridemen menyeluruh di tempat peradangan. Deformitas Haglund dapat dikoreksi dengan *osteotomy calcaneus* posterior, dan kalsifikasi pada insersi Achilles yang harus dilepaskan. Oleh karena daerah kalsifikasi terletak di distal tendon Achilles, *suture anchor* merupakan metode pilihan terbaik untuk mendapatkan fiksasi yang stabil dari tendon.

**Kesimpulan:** Reseksi tulang untuk deformitas Haglund dan debridement serta suture anchor repair adalah perawatan bedah yang efektif untuk Achilles tendinopathy.

**Key words:** Achilles tendinopathy, insertional Achilles tendinopathy, Haglund deformity, bony resection, suture anchor.

---

**Corresponding author:** Ihsan Oesman, MD, ihsan\_oesman@yahoo.com

## INTRODUCTION

Achilles tendon has a unique functional anatomy, and because of the large size, this tendon is susceptible for acute and chronic injury.<sup>1</sup> Achilles tendon is the strongest and the thickest tendon in the human body, which composed of fibers from gastrocnemius and soleus muscles.<sup>2</sup> The trend of the incidence of Achilles tendon injury is increasing.<sup>3</sup> The causes of the injury are multifactorial like overuse and overload mechanisms with patient susceptibility.<sup>4</sup> Achilles tendon injury can be divided into internal and external factors influencing the disease. The internal factors comprises of anatomical and systemic diseases, including decreased blood supply, corticosteroid use and also the male gender. The external factors comprises, for example, high intensity exercise, improper footwear size and irregular training surface.<sup>5-7</sup>

According to the American Academy of Orthopaedics Surgeon (AAOS), there are five types of Achilles tendinopathy different in histology, clinical signs and treatment. The first one, Insertional Tendinopathy, is the degeneration of tendon at their insertion at the calcaneus. This condition is associated with corticosteroid use, hypertension, diabetes, obesity, gout and also the use of quinolone antibiotics.<sup>8,9</sup> Haglund deformity, which is bony prominence of the posterior-superolateral of the calcaneus bone, is associated with this insertional condition. At the initial phase, it is an inflammatory process, but in chronic cases, the inflammatory process is thought to be dismissed. The symptoms are pain and stiffness of the calcaneus that aggravate activities and exercise. Enlarging posterior border of the calcaneus is also observed.<sup>8,9</sup>

Second type of tendinopathy is Retrocalcaneal Bursitis, by definition it is an inflammation of retrocalcaneal bursa and may lead to Achilles tendon degeneration. The clinical symptom is pain anterior to Achilles tendon and superior to calcaneus, with positive two-finger squeeze test.<sup>10</sup> The rest of the Achilles tendinopathy types were non-insertional tendinopathies divided into three histopathologic: paratenonitis, tendinosis and combination of paratenonitis and tendinosis. Paratenonitis is an inflammation that only occurs in the paratenon, it may thicken and adhere to the tendon. Paratenonitis histology comprises of inflammatory cell infiltrate and capillary proliferation in paratenon with normal Achilles tendon. The clinical description is swelling, pain, tenderness and warmth over the tendon.<sup>8</sup> Tendinosis is intratendinous degeneration due to atrophy.

The histological specimen shows collagen degeneration, hypocellularity, fiber disorientation and local necrosis. Physical examination demonstrates palpable tendon nodule that asymptomatic without swelling of the tendon sheath.<sup>11</sup> The last is the combination of both paratenonitis and tendinosis, in which the histological and clinical signs are mixed within the two types.

The common treatment for most cases of insertional Achilles tendinopathy is nonoperative, consisting of short period of immobilization and gradual integration to reduce heavy load activities plus physiotherapy to relieve pain.<sup>12</sup> Some literature reported that the Platelet-rich plasma (PRP) therapy could be used for refractory cases, although there were little evidence.<sup>13,14</sup> Surgical treatment for this condition is indicated for chronic type that failed with conservative treatment. The goal is to remove the diseased portion of the tendon with thorough debridement, resection of bony prominence irritating the tendon, and repair the tendinous insertion.<sup>12,15</sup>

Non-insertional Achilles tendinopathy treatment are mostly conservative. Rest, ice, compression, training and lifestyle modifications, analgesics, orthotic and night splint may be used as treatments. Some evidence suggested that extracorporeal shock wave therapy may have good result for refractory cases, whereas no evidence for local injection speeding up the recovery.<sup>16,17</sup> Indication for surgery is for cases failed to conservative treatments. Surgery includes endoscopy and open surgery to remove inflamed paratenon, release of plantar tendon, debridement of the degenerative tendon material and defect repair.<sup>18,19</sup>

## CASE ILLUSTRATION

We report a case of a male, 69 years old, with five years suffering from pain in the left heel. The pain aggravated in standing position and whenever he had activities. Beside the pain, the patient sometimes also feels burning sensation in the heel when he walked. This uncomfortable condition made the heel progressively developed swelling and stiffness.

Like any other degenerative condition, the patient, at first, did not go to visit a doctor. He tried to treat himself with analgesics and continued his activities as a lecturer. However, the swelling kept happening and since one year ago, the swelling did not subside. The patient then came to see a physiotherapist to get a schedule for a training program. The pain resolved but the heel bump

persisted. The patient then came to our clinic and was recommended to get an MRI examination. Because the deformity and the intermittent pain could not be treated with conservative treatments, the patient underwent a surgery.

From physical examination, there was marked swelling posterior to the left ankle. The swelling did not have any inflammation signs, which confirmed a chronic condition. From the lateral foot x-ray examination, it was shown soft tissue calcification at the posterior of the os calcaneus with swelling at the surrounding soft tissues. This site of calcification was at the site of the insertion of the Achilles tendon, which confirmed with MRI. Also, it was shown clearly Haglund deformity, a horn-like bony prominence at the superior-posterior calcaneus.

From the MRI examination, it was found enthesophyte fragmentation with bone marrow edema at the posterior calcaneus. Enthesophyte is a bony spur that can grow onto a bone at the point of attachment of tendons and/or ligaments. In our case, the enthesophyte was located at the insertional site of the Achilles tendon, along with the tendon edema surrounding it.

We did surgical procedure to the patient in prone position under tourniquet control. The Achilles tendon was split using a midline approach. After exposing the posterior of the calcaneal, we decided to detach the insertional Achilles tendon to calcaneus. We found that the distal Achilles tendon was locally damaged. Any granulation tissue anterior to the tendon was debrided. We also removed the retrocalcaneal bursae appeared as non-healthy tissues.

We palpated the heterotrophic calcification inside the distal of the Achilles tendon. We removed all the calcification but maintained the length as long as possible carefully tried not to leave any diseased tendon. Posterior calcaneus showed a sufficiently big Haglund deformity and resection of the bony prominence was conducted. The resection was performed with a sagittal saw and c-arm was used to confirm an even and complete resection of the posterosuperior corner of the bone.

The detachment site of the tendon was then reattached to the tuberosity of the calcaneus that already osteotomized using a suture anchor. Lastly, the tendon was grasped with Prolene sutures using a Krakow technique and pulled into a prepared bony bed while placing the foot in resting equine position. We used dorsal slab to hold the slight plantarflexion position to allow soft tissue healing.

For evaluation of the outcome of the surgery, we used ATRS (Achilles Tendon Total Rupture Score). The ATRS is a patient-reported instrument developed in 2007 to evaluate the outcomes after treatment. It consists of ten items evaluating aspect of symptoms and functions. Our patient had ATRS score of 34 pre-operatively, and a month after the surgery the patient had ATRS score of 58.

## DISCUSSION

Achilles tendon, which has paratenon that allows for gliding motion of the tendon, is composed of flexible connective tissues.<sup>20</sup> Paratenon is hyper-vascular and in contrast, the Achilles tendon itself is hypo-vascular.<sup>21</sup> When running, the Achilles tendon receives load up to 12.5 times of the body weight, make it vulnerable to injury.<sup>22</sup> There is also anatomical difference in this tendon between gender. Male have larger cross-sectional area than female, so they have higher maximum tendon rupture force and stiffness. Also, in older patients, they have lower maximum tendon rupture force and lower stiffness than the younger ones.<sup>23</sup> The study of Kvist *et al*, consisted of 698 patients, reported that 66% patients had Achilles tendinopathies and 23% had insertional problems. Eighty nine percent patients were men.<sup>24</sup>

Muscle strength, power, endurance and flexibility are important parts of performance and can prevent sport injuries, especially tendon injury.<sup>25</sup> If there are any muscle weaknesses, the capacity of the tendon will reduce and the muscle itself cannot protect the tendon from strain injury and this will generate irritation and pain.<sup>26</sup> This was explained in our patient who had prior lumbar surgery due to hernia nucleus pulposus, in which we knew that HNP will affect the muscular strength.

Repetitive strain of the Achilles tendon will cause the so-called overuse tendon injury, making the tendon unable to endure tensile stress. From this condition, the tendon fibers start to disrupt microscopically leading to pain and inflammation. Running with high intensity, monotonous, asymmetric with poor technique are the risk factors of overuse tendon injury.<sup>27</sup>

The most irritating and disconcerting symptoms of the Achilles tendinopathy is the pain. Initially, the pain is considered as associated with chronic tendinopathy as the result of inflammation, collagen tissue separation or tissue degeneration.<sup>28</sup> But this hypothesis is weak for many chronic Achilles tendon have no evidence of

inflammation, and actually, the tendon degeneration is not supposed to cause pain.<sup>29</sup> An alternative explanation describes unidentified biochemical noxious compounds (such as, for example, chondroitin sulfate, glutamate, calcitonin) or neovascularization of Achilles tendon that may cause irritation to the pain receptors.<sup>29</sup>

Achilles tendinopathy in acute phase will generate swollen tendon, tenderness and also crepitation. In a more chronic phase, the pain persisted during activities is still the cardinal symptom together with localized/nodular swelling. Specifically, in patient with tendinosis, the focal nodule may move as the ankle is dorsiflexed and plantarflex.<sup>30,31</sup> Our patient had a nodular swelling but the swelling was immobile.

Haglund deformity is a bony prominence of the posterior-superolateral of the calcaneus bone affecting the soft tissue at the retrocalcaneal space, including the Achilles tendon.<sup>32</sup> Our patient had an obvious Haglund deformity and could be observed at the clinical and radiological examination.

Tendon thickening is found on the sagittal images of the MRI examination in patients with chronic Achilles tendinopathy. Movin *et al*, suggested that increased amount of interfibrillar non-collagen matrix and altered fiber structure will enhance in MRI signaling with gadolinium.<sup>33</sup> However, there was only insertional contrast enhancement of the patient in our study.

The goal of the conservative treatment is controlling the inflammation and correcting the training errors, the limb malalignment, decreased flexibility, muscle weaknesses, and the use of poor equipments during sports.<sup>34</sup> Control of inflammation is performed by decreasing the activities, cold packs and anti-inflammatory medication.<sup>35</sup> Study from Niesen-Vertommen stated that for chronic Achilles tendinopathy, eccentric training is superior than concentric training to decrease pain.<sup>36</sup> This study is similar to Alfredson *et al*, who reported that the use of intensive eccentric muscle training for the treatment of chronic cases gave promising results.<sup>37</sup>

There are many literature describing each method of surgical treatment in Achilles tendinopathy. The approach of surgical treatment can be divided into minimal invasive (endoscopically) and open surgery. Calcaneoplasty with debridement of retrocalcaneal bursa may be conducted endoscopically.<sup>38</sup> The outcome of this technique achieves good/excellent result in 75-95% cases, but infrequent complication, such as rupture of the

tendon, may encountered.

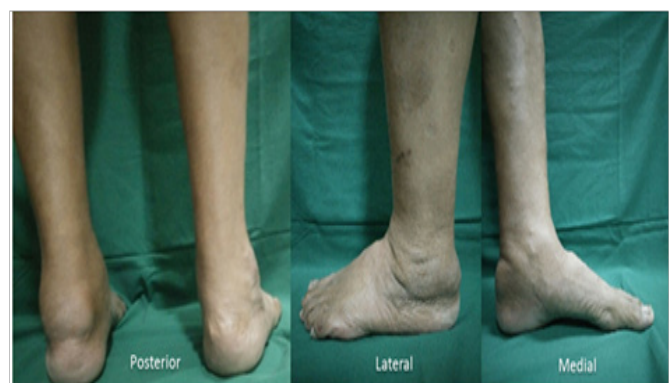Another choice is open surgery, the surgical goal is to include thorough debridement of the degeneration and calcification, decompression of the surrounding soft tissues, resection of the bone prominence, reattachment or repair of the insertion, and/or augmentation of the tendon Achilles with a graft/tendon transfer.<sup>39</sup> In our case, we did debridement of the heterotrophic bone enthesophyte, resection of the Haglund deformity and repairment using suture anchor. We did not use tendon augmentation or transfer because we could still maintain the length of the Achilles tendon.

If any evidence of intra-tendinous lesion is seen in preoperative imaging such as MRI, many authors suggest longitudinal incision over the thickened area and excision of the granulated tissue in the necrotic area.<sup>40</sup> Numerous incisions are described, including longitudinal tendon splitting, medially-based incisions, Cincinnati/transverse and laterally-based incisions. There appears to be no significant benefit of one over another in the issued series.<sup>39</sup>

Based on clinical data, up to 50% of the tendon attachment can be safely debrided with minimal complication of re-rupture. Repairment or reattachment can use bone anchor or trans-osseous sutures. Recent data shows that there is no difference in the load to failure ratio between single row or double row repair.<sup>41</sup> Nunley *et al*, performed another study that show they did not do routine augmentation in 70% debridement, but still achieved 96% satisfaction with good functional outcome.<sup>42</sup>

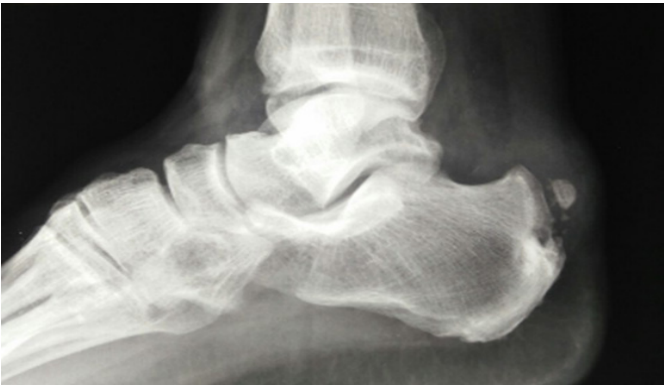### Acknowledgement

We would like to express our deep gratitude to all contributors and we hereby affirm that there is no conflict of interest regarding this work.

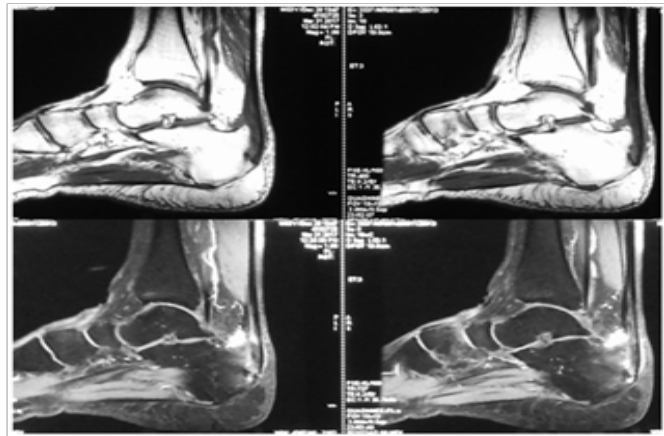


**Figure. 1 a-b..** Clinical picture of swelling at posterior left ankle. The picture shows the difference with contralateral side.

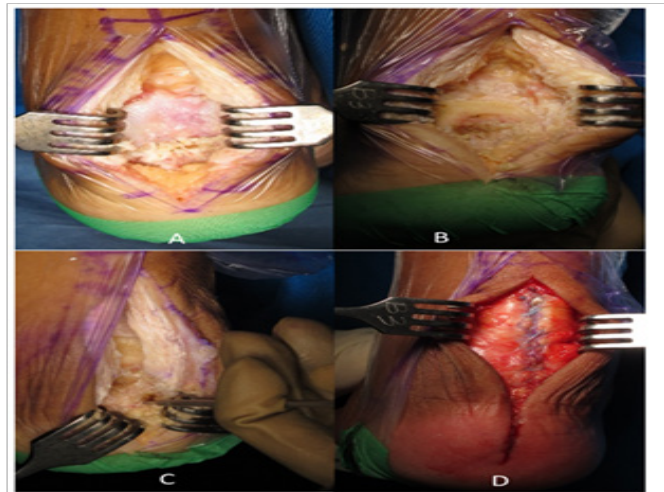




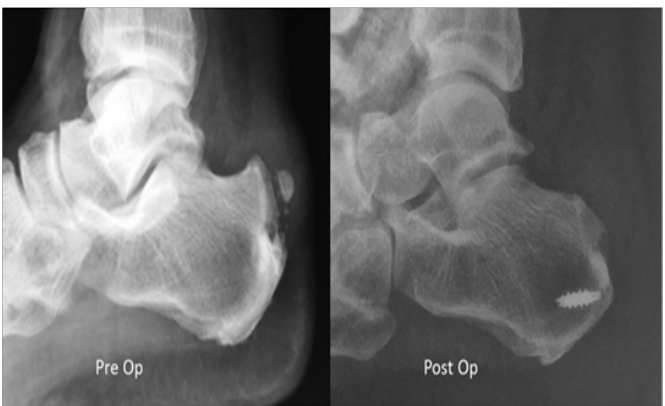
**Figure. 3** a-d. . The sagittal T1 (upper) and sagittal T2 (lower) picture that confirm the calcification, tendon and bone marrow edema around insertional Achilles tendon.



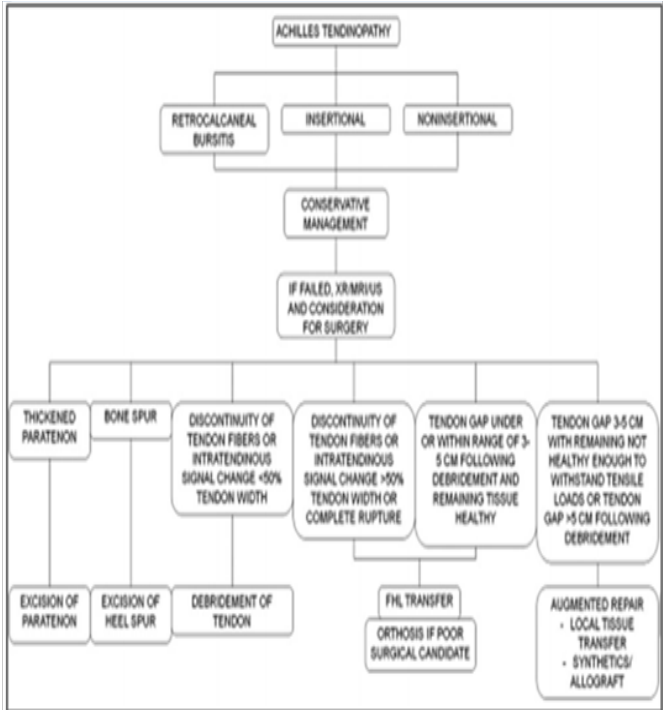**Figure. 3** a-d. . The sagittal T1 (upper) and sagittal T2 (lower) picture that confirm the calcification, tendon and bone marrow edema around insertional Achilles tendon.



**Figure. 4.** (A) Exposed of the posterior calcaneus. (B) After calcaneal osteotomy. (C) Suture anchor insertion. (D) Achilles tendon suturing



**Figure. 5** a: Post operative Xray with marked suture anchor and resected bony prominence.



**Figure. 6.** Treatment algorithm for management of the wide variety of Achilles tendon pathology

REFERENCES

1. Myerson MS, McGarvey W. Disorders of the Achilles tendon insertion and Achilles tendinitis. Instr Course Lect. 1999;48:211–8.
2. Doral MN, Alam M, Bozkurt M, Turhan E, Atay OA, D?nmez G, et al. Functional anatomy of the Achilles tendon. Knee Surg Sports Traumatol Arthrosc. 2010 May;18(5):638–43.
3. Syha R, Springer F, Ketelsen D, Ipach I, Kramer U, Horger M, et al. Achillodynia - radiological imaging of acute and chronic overuse injuries of the achilles tendon.

- ROFO Fortschr Geb Rontgenstr Nuklearmed. 2013 Nov;185(11):1041–55.
4. Riley G. The pathogenesis of tendinopathy. A molecular perspective. *Rheumatol Oxf Engl*. 2004 Feb;43(2):131–42.
5. Maffulli N. Rupture of the Achilles tendon. *J Bone Joint Surg Am*. 1999 Jul;81(7):1019–36.
6. White DW, Wenke JC, Mosely DS, Mountcastle SB, Basamania CJ. Incidence of major tendon ruptures and anterior cruciate ligament tears in US Army soldiers. *Am J Sports Med*. 2007 Aug;35(8):1308–14.
7. Hess GW. Achilles tendon rupture: a review of etiology, population, anatomy, risk factors, and injury prevention. *Foot Ankle Spec*. 2010 Feb;3(1):29–32.
8. Saltzman CL, Teare DS. Achilles tendon injuries. *J Am Acad Orthop Surg*. 1998 Oct;6(5):316–25.
9. Schepsis AA, Jones H, Haas AL. Achilles tendon disorders in athletes. *Am J Sports Med*. 2002 Apr;30(2):287–305.
10. Reddy SS, Pedowitz DI, Parekh SG, Omar IM, Wapner KL. Surgical treatment for chronic disease and disorders of the Achilles tendon. *J Am Acad Orthop Surg*. 2009 Jan;17(1):3–14.
11. Battery L, Maffulli N. Inflammation in overuse tendon injuries. *Sports Med Arthrosc Rev*. 2011 Sep;19(3):213–7.
12. McGarvey WC, Palumbo RC, Baxter DE, Leibman BD. Insertional Achilles tendinosis: surgical treatment through a central tendon splitting approach. *Foot Ankle Int*. 2002 Jan;23(1):19–25.
13. Di Matteo B, Filardo G, Kon E, Marcacci M. Platelet-rich plasma: evidence for the treatment of patellar and Achilles tendinopathy--a systematic review. *Musculoskelet Surg*. 2015 Apr;99(1):1–9.
14. de Vos RJ, Weir A, van Schie HTM, Bierma-Zeinstra SMA, Verhaar JAN, Weinans H, et al. Platelet-rich plasma injection for chronic Achilles tendinopathy: a randomized controlled trial. *JAMA*. 2010 Jan 13;303(2):144–9.
15. Ortmann FW, McBryde AM. Endoscopic bony and soft-tissue decompression of the retrocalcaneal space for the treatment of Haglund deformity and retrocalcaneal bursitis. *Foot Ankle Int*. 2007 Feb;28(2):149–53.
16. Clement DB, Taunton JE, Smart GW. Achilles tendinitis and peritendinitis: etiology and treatment. *Am J Sports Med*. 1984 Jun;12(3):179–84.
17. Mani-Babu S, Morrissey D, Waugh C, Screen H, Barton C. The effectiveness of extracorporeal shock wave therapy in lower limb tendinopathy: a systematic review. *Am J Sports Med*. 2015 Mar;43(3):752–61.
18. Kader D. Achilles tendinopathy: some aspects of basic science and clinical management. *Br J Sports Med*. 2002 Aug 1;36(4):239–49.
19. Steenstra F, van Dijk CN. Achilles tendoscopy. *Foot Ankle Clin*. 2006 Jun;11(2):429–438, viii.
20. O'Brien M. Functional anatomy and physiology of tendons. *Clin Sports Med*. 1992 Jul;11(3):505–20.
21. Chen TM, Rozen WM, Pan W-R, Ashton MW, Richardson MD, Taylor GI. The arterial anatomy of the Achilles tendon: anatomical study and clinical implications. *Clin Anat N Y N*. 2009 Apr;22(3):377–85.
22. Benjamin M, Toumi H, Ralphs JR, Bydder G, Best TM, Milz S. Where tendons and ligaments meet bone: attachment sites ('entheses') in relation to exercise and/or mechanical load. *J Anat*. 2006 Apr;208(4):471–90.
23. Maffulli N, Longo UG, Ronga M, Khanna A, Denaro V. Favorable outcome of percutaneous repair of Achilles tendon ruptures in the elderly. *Clin Orthop*. 2010 Apr;468(4):1039–46.
24. Kvist M. Achilles tendon injuries in athletes. *Ann Chir Gynaecol*. 1991;80(2):188–201.
25. Kannus P, Niittymäki S, Järvinen M, Lehto M. Sports injuries in elderly athletes: a three-year prospective, controlled study. *Age Ageing*. 1989 Jul;18(4):263–70.
26. Dirix A, Knuttgen HG, Tittel K, International Olympic Committee, International Federation of Sports Medicine, editors. *The Olympic book of sports medicine*. Pbk. reissue. Oxford ; Boston : St. Louis, Mo: Blackwell Scientific Publications ; Distributors, USA, Mosby-Year Book; 1991. 692 p. (Encyclopaedia of sports medicine).
27. Paterno MV, Taylor-Haas JA, Myer GD, Hewett TE. Prevention of Overuse Sports Injuries in the Young Athlete. *Orthop Clin North Am*. 2013 Oct;44(4):553–64.
28. Khan KM. Where is the pain coming from in tendinopathy? It may be biochemical, not only structural, in origin. *Br J Sports Med*. 2000 Apr 1;34(2):81–3.
29. Khan KM, Cook JL. Overuse Tendon Injuries:: Where Does the Pain Come From? *Sports Med Arthrosc Rev*. 2000 Jan;8(1):17–31.
30. Leppilahti J, Orava S, Karpakka J, Takala T. Overuse injuries of the Achilles tendon. *Ann Chir Gynaecol*. 1991;80(2):202–7.
31. Galloway MT, Jokl P, Dayton OW. Achilles tendon overuse injuries. *Clin Sports Med*. 1992 Oct;11(4):771–82.
32. Natarajan S, Narayanan V. Haglund Deformity ? Surgical Resection by the Lateral Approach. *Malays Orthop J*. 2015 Mar 1;9(1):1–3.
33. Movin T, Gad A, Reinholt FP, Rolf C. Tendon pathology in long-standing achillodynia. Biopsy findings in 40 patients. *Acta Orthop Scand*. 1997 Apr;68(2):170–5.
34. Alfredson H, Lorentzon R. Chronic Achilles tendinosis: recommendations for treatment and prevention. *Sports*

- Med Auckl NZ. 2000 Feb;29(2):135–46.
35. Hess GP, Cappiello WL, Poole RM, Hunter SC. Prevention and treatment of overuse tendon injuries. *Sports Med Auckl NZ*. 1989 Dec;8(6):371–84.
  36. Morrissey D, Roskilly A, Twycross-Lewis R, Isinkaye T, Screen H, Woledge R, et al. The effect of eccentric and concentric calf muscle training on Achilles tendon stiffness. *Clin Rehabil*. 2011 Mar 1;25(3):238–47.
  37. Mafi N, Lorentzon R, Alfredson H. Superior short-term results with eccentric calf muscle training compared to concentric training in a randomized prospective multicenter study on patients with chronic Achilles tendinosis. *Knee Surg Sports Traumatol Arthrosc*. 2001 Jan;9(1):42–7.
  38. Jerosch J, Schunck J, Sokkar SH. Endoscopic calcaneoplasty (ECP) as a surgical treatment of Haglund's syndrome. *Knee Surg Sports Traumatol Arthrosc Off J ESSKA*. 2007 Jul;15(7):927–34.
  39. Roche AJ, Calder JDF. Achilles tendinopathy: A review of the current concepts of treatment. *Bone Jt J*. 2013 Oct 1;95-B(10):1299–307.
  40. Paavola M, Kannus P, Järvinen TAH, Khan K, Józsa L, Järvinen M. Achilles tendinopathy. *J Bone Joint Surg Am*. 2002 Nov;84-A(11):2062–76.
  41. Pilson H, Brown P, Stitzel J, Scott A. Single-row versus double-row repair of the distal Achilles tendon: a biomechanical comparison. *J Foot Ankle Surg Off Publ Am Coll Foot Ankle Surg*. 2012 Dec;51(6):762–6.
  42. Nunley JA, Ruskin G, Horst F. Long-term clinical outcomes following the central incision technique for insertional Achilles tendinopathy. *Foot Ankle Int*. 2011 Sep;32(9):850–5.