

Clinical Research

Comparative between standard dynamic hip screw and cemented bipolar arthroplasty in trochanteric fracture of femur in elderly patient

Herbert Yurianto,¹ Idrus Paturusi,² Henry Yurianto,³ Muhammad Sakti,⁴ Supriyadi⁵

^{1,2,3,4,5} Department of Orthopaedic & Traumatology, Faculty of Medicine, Universitas Hasanuddin, Makassar

ABSTRACT

Introduction: Unstable intertrochanteric fracture in elderly is a very disturbing condition for patients. This research is aimed to compare the clinical functional results between the standard dynamic hip screw (DHS) and the cemented bipolar arthroplasty in elderly patients with unstable femur intertrochanteric fracture. Unstable femur intertrochanteric fracture in elderly patients represented the very disturbing condition in the patients' health history.

Methods: This research was conducted in January to February 2016. The patients' medical data were the secondary data, and the interview results were the primary data. This was an analytic cross-sectional study. The data were analyzed by cross tabulation, Chi-square test, and Mann-Whitney U-test. Out of 38 samples, 21 samples are of DHS, and 17 samples are of cemented bipolar arthroplasty.

Results: In the clinical functional data based on Wilson and Salvati's score system, there was no significant difference between both groups ($p > 0.05$). There was no difference in the score of walking and its function ($p > 0.05$). The time-to-weight-bearing was significantly different in the DHS and the bipolar groups with p value of < 0.001 . DHS treatment gave better and more significant pain score of the muscular strength and motion than the group with bipolar treatment.

Conclusion: There is no significant difference in clinical function results based on the Salvati and Wilson's score between DHS and Cemented Bipolar Arthroplasty in both groups.

ABSTRAK

Pendahuluan: Fraktur intertrokanter yang tidak stabil pada lansia merupakan kondisi yang sangat mengganggu bagi pasien. Penelitian ini bertujuan untuk membandingkan hasil fungsional klinis antara Dynamic Hip Screw (DHS) dan artroplasti bipolar dengan semen pada pasien usia lanjut dengan faktor intertrokanter femur yang tidak stabil. Faktor intertrokanter femur yang tidak stabil pada pasien lanjut usia merupakan kondisi yang sangat mengganggu dalam riwayat kesehatan pasien.

Metode: Penelitian ini dilakukan dari Januari hingga Februari 2016. Data medis pasien adalah data sekunder, dan hasil wawancara sebagai data primer. Studi ini merupakan analisis cross-sectional. Data dianalisis dengan tabulasi silang, uji Chi-square, Mann-Whitney U-test. Dari 38 sampel, 21 sampel ditangani dengan DHS, dan 17 sampel ditangani dengan artroplasti bipolar dengan semen.

Hasil: Penilaian fungsional klinis menggunakan sistem skor Wilson dan Salvati tidak menunjukkan perbedaan signifikan antara kedua kelompok ($p > 0,05$). Tidak ada perbedaan pada skor berjalan dan fungsinya ($p > 0,05$). Waktu untuk menopang berat badan berbeda secara signifikan pada kelompok DHS dan bipolar dengan nilai $p < 0,001$. Kelompok DHS memiliki skor nyeri yang lebih baik dan kekuatan serta gerakan otot yang signifikan dibanding kelompok dengan pengobatan bipolar.

Kesimpulan: Tidak ada perbedaan signifikan dari hasil fungsi klinis berdasarkan skor Salvati dan Wilson antara DHS dan artroplasti bipolar dengan semen pada kedua kelompok.

Keywords: Unstable intertrochanteric fracture, Dynamic Hip Screw, Cemented Bipolar Arthroplasty, Wilson and Salvati's score system, time-to-weightbearing.

Corresponding author : Herbert Yurianto, MD, hyurianto@yahoo.com

INTRODUCTION

Hip fracture in elderly is a disturbing condition for healthy patients. In the healthcare system and in the society in general, fracture of intertrochanter femur and fracture of the neck femur is an epidemic condition. Incidence of intertrochanter femur fracture is 57% of all fracture in the hip region.¹ Incidence of intertrochanter femur fracture seems to increase in concordance with the increasing life expectancy in the world. Gallagher, *et al.*, reported that there is an 8-fold increase of incidence of intertrochanteric femur fracture in male over 80 years old, and 5-fold increase in female over 80 years old. Lawton, *et al.*, reported that patients with intertrochanter femur fracture have older age compared to those with neck femur fracture.

The aim for management of the fracture nowadays is not only to fix the anatomical position but also to support the early mobilization of the lower limb. Early functional activity rehabilitation in the rigidly fixated fracture improve bone healing, maintain muscle tone, and increase the range of motion to normal, prevent complication from prolong immobilization and help maintaining self-confidence and psychological health.

Intertrochanteric femur fracture can be divided into stable and unstable type according to Evans classification.² Stable intertrochanter femur usually managed by dynamic hip screw, with a failure rate of less than 2%. Dynamic hip screw is a lag screw that biomechanically superior than several types of compression hip screw system that have already been developed lately.³ Sliding mechanism maintain the inter-fragment contact even if resorption of the distal part fracture happens. Unstable intertrochanter femur fracture managed with dynamic hip screw have a higher failure rate with a range of 4% to 15%.⁴ Collapsed bone, disrupted fixation and cutout from the lag screw are the problems that occur in elderly with an unstable intertrochanteric femur fracture.⁵

Even though the failure rate is quite high from the literature, in Orthopaedic and Traumatology Department of Hasanuddin University, the dynamic hip screw is still the treatment of choice for unstable intertrochanteric femur fracture.⁶ In this study, the writer wanted to evaluate other operation techniques that is recommended for unstable intertrochanter femur, i.e. cemented bipolar hemiarthroplasty.⁷ This study is held to compare the clinical functional outcome between the standard dynamic

hip screw and the cemented bipolar arthroplasty in the elderly with unstable intertrochanter femur fracture.

METHODS

Subjects

Subjects of this study are elderly patients with age ≥ 50 years old with unstable intertrochanteric femur fracture who were treated with standard dynamic hip screw and cemented bipolar arthroplasty at Wahidin Sudirohusodo hospital and affiliated hospitals (Hasanuddin University Hospital, Stella Maris Hospital, Pelamonia Hospital) of Orthopedic and Traumatology departments of Faculty of Medicine, Hasanuddin University, Makassar, from January 2012 to December 2015

Parameter

The hip joint clinical functional outcome is evaluated using Salvati and Wilson score and time-to-weight bearing

Ethics

This study was commenced after the ethical clearance was acknowledge by the Ethical Committee of Medical Studies of Faculty of Medicine, Hasanuddin University. All expenses are covered by the authors

Statistics

This study used Analytic Cross-Sectional Study design. Acquired data was processed using SPSS for Windows version 22. Statistic tests used in this study are descriptive cross-tabulation, Chi-square test, and Mann-Whitney U test.

RESULTS

There were 38 subjects in total that underwent the analysis. Subjects were divided into two groups according to the management, the Dynamic Hip Screw group consisted of 21 persons and Bipolar group consisted of 17 persons. The age criteria for this study was 51 – 90 years old, the mean was 70 ± 11 years old. The distribution of the subject's age was even in both groups.

From the Wilson and Salvati score, the pain score with muscle power and motion variable were significantly different between the DHS group and the Bipolar group ($p < 0.5$). The DHS group had higher score in both pain score and muscle power and motion score compared to the bipolar group. But in the walking and function

score, both groups didn't show any significant difference ($p>0.05$).

Overall, from the total score and the time-to-weight-bearing, there was a significant difference between the DHS group and the Bipolar group with $p<0.05$.

From the functional outcome, there was no significant difference between the two groups ($p>0.05$). But the DHS group gave the highest functional outcome with a very good functional outcome (66.7%) compared to the bipolar group, in which the highest percentage was good functional outcome (41.2%).

Table 1. Functional outcome score and time-to-weightbearing comparison

Variables	Implant	N	Mean	SD	P
Pain	DHS	21	8,4	2,2	0,003
	Bipolar	17	6,5	1,9	
Walking	DHS	21	6,4	2,6	0,561
	Bipolar	17	6,4	1,9	
Muscle strength and motion	DHS	21	9,2	1,6	0,000
	Bipolar	17	6,8	1,7	
Function	DHS	21	7,3	4,0	0,209
	Bipolar	17	6,8	3,0	
Total	DHS	21	31,3	8,7	0,015
	Bipolar	17	26,5	7,9	
TWB (days)	DHS	20	91,5	38,3	0,000
	Bipolar	17	3,5	0,5	

Table 2. Comparison of Functional Outcome Score between DHS and Bipolar

		Implant		
Functional Outcome		DHS	Bipolar	Total
Bad	N	1	2	3
	%	4,8%	11,8%	7,9%
Average	N	4	2	6
	%	19,0%	11,8%	15,8%
Well	N	2	7	9
	%	9,5%	41,2%	23,7%
Very Well	N	14	6	20
	%	66,7%	35,3%	52,6%
Total	N	21	17	38
	%	100,0%	100,0%	100,0%

DISCUSSION

This study is to show that hip fracture in the elderly could be a nuisance for healthy patients. Stable intertrochanteric femur fracture is usually managed by

dynamic hip screw, with a failure rate less than 2%. Unstable intertrochanteric femur fracture managed by dynamic hip screw has higher failure rate ranging from 4% to 15%. Another choice of management for unstable intertrochanteric femur fracture is hemiarthroplasty.⁵ The aim of the fracture management for now is not only to reduce to anatomical position but also to support early mobilization from the lower limb and articulation.⁸

Various studies have shown good results with bipolar hemiarthroplasty for unstable intertrochanteric fracture compared to dynamic hip screw (DHS). From the result of this study, according to Salvati and Wilson functional outcome score, it is shown that there is no significant difference between the management of unstable intertrochanter femur fracture using DHS and bipolar hemiarthroplasty.⁹ This may be caused by the duration of follow up that exceeded 90 days (3 months). If further evaluation was done according to each characteristic score, particularly for the pain score with muscle tone and motion, the group managed with the DHS had significant benefits compared to the group treated with bipolar. But for the walking score and function, there was no significant difference between the two groups. Bias may occur in this study due to the orthopaedic surgeons

managing the unstable intertrochanter femur fracture had their own preferences in using DHS or bipolar.¹⁰ Other factors may also affect this study. The management with bipolar should be further evaluated since removal of or stitches to a part of the muscle will affect the pain and the muscle power. On the contrary, DHS doesn't excise any soft tissues.¹¹

In the time-to-weight-bearing evaluation, the group managed with bipolar had an advantage compared to that managed with DHS ($p < 0.001$). The mean time-to-weight-bearing for DHS group was 91.5 days, on the other hand, the bipolar group was only 3.5 days.

This is suitable with what Walia, *et al* (2012) stated that

higher rate of complication is related to immobilization, bed rest, physical therapy and weight-bearing. According to Grimsrud in Walia, *et al* (2012), usage of cemented bipolar hip arthroplasty improved the weight-bearing with low rate of complication. This was also supported by the study of Zhang, *et al* (2011)¹², and another study of Walia *et al* (2012). This result is suitable with the study that stated the patients managed with cemented bipolar hip arthroplasty did not need to delay weight-bearing.

According to the study of Sinno, *et al* (2010), the usage of cemented bipolar hemiarthroplasty had lower risks of non-weight-bearing complication compared to internal fixation.¹³ This is also shown in the functional outcome of patients with 1 year survival after operation, cemented

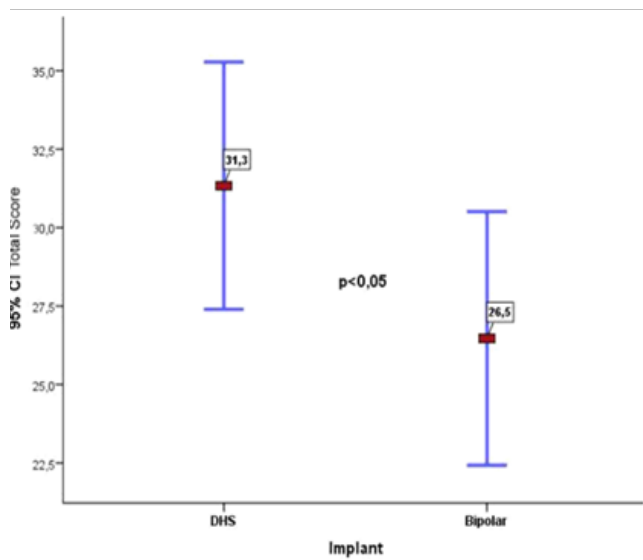


Figure 1. Comparison of total clinical functional score between DHS and Bipolar

bipolar hemiarthroplasty is better compared to the management using DHS for unstable intertrochanter femur fracture.¹⁴

CONCLUSION

There is no significant difference for functional outcome according to Salvati and Wilson Score between the dynamic hip screw (DHS) and the cemented bipolar arthroplasty in the elderly with unstable intertrochanteric femur fracture. The group that was managed with DHS had better pain score and muscle power and motion compared to that managed with bipolar. There was no significant difference for walking score and motion between the dynamic hip screw (DHS) group and the cemented bipolar arthroplasty group. As for the time-to-weight-

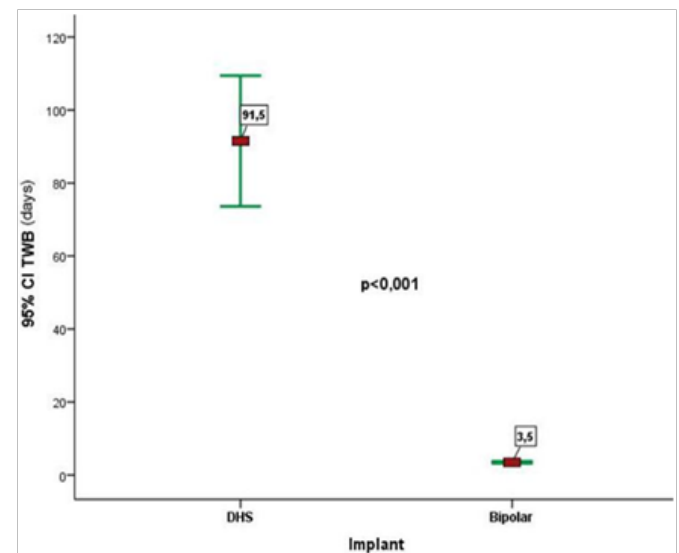
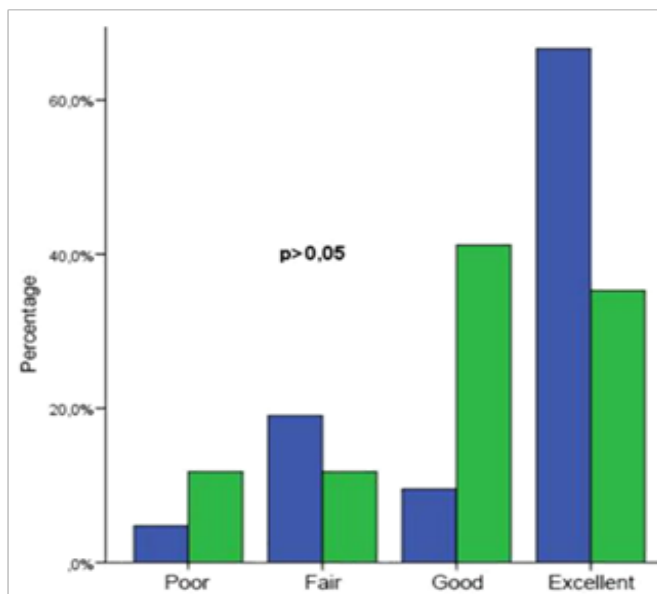


Figure 2. Comparison of time-to-weightbearing between DHS and Bipolar

bearing score, the group managed with bipolar had further advantage compared to that with DHS.

Conflict of interest

The authors declare that there is no conflict of interest. The authors did not receive grants or outside funding in support of this research or preparation of the manuscript. The authors did not receive any payments or other benefits or any commitments or agreements to provide such benefits from a commercial entity. No commercial entity paid or directed, or agreed to pay or direct, any benefits to any research fund, foundation, educational institution, or other charitable or nonprofit organization with which the authors are affiliated or associated.



Implant : ■ DHS ■ Bipolar

Figure 3. Comparison of Functional Outcome between DHS and Bipolar

REFERENCES

- Egol KA, Koval KJ and Zuckerman JD. Intertrochanteric Fractures. In: Egol KA, Koval KJ and Zuckerman JD [eds.]. Handbook of Fractures 5th ed. Philadelphia: Wolters Kluwer; 2015.
- Thompson JC. Netter's Concise Orthopaedic Anatomy 2nd ed. Philadelphia: Saunders Elsevier; 2010.
- Robling AG, Castillo AB, and Turner CH. Biomechanical and Molecular Regulation of Bone Remodelling. Annu Rev Biomed Eng 2006. 8: 455-98.
- Shuller FD and Schmitz Mweiss DB, Milewski MD, Thompson SR, and Stannard JP. Trauma. In: Miller MD, Thompson SR and Hart JA [eds.]. Review of Orthopaedics 5th ed. Philadelphia: Saunders; 2008: 747-48.
- Kiran Kumar GN, Menna S, Vijaya Kumar N, Manjunath S, dan Binaya Raj MK. Bipolar Hemiarthroplasty in Unstable Intertrochanteric Fractures in Elderly: A Prospective Study. Journal of Clinical and Diagnostic Research 2013. 7 (8): 1660-71.
- Ingle M, Sonar U, Koichade Mr, Yelne A, Ashish R. Cemented Bipolar Hemiarthroplasty in Unstable Osteoporotic Fractures of Intertrochanteric Neck Femur in Elderly Patients: A Prospective Study. Indian journal of Basic and Applied Medical Research 2014. 3(3): 85-94.
- Patil A, Ansari M, Pathak A, Goregaonkar AB and Thakker CJ. Role of Cemented Bipolar Hemiarthroplasty for Comminuted Inter-trochanteric Femur Fracture in Elderly Osteoporotic Patients Through a Modified Transtrochanteric approach – "SION Hospital Modification". IOSR Journal of Dental and Medical Sciences 2013. 9 (4): 40-47.
- Walia JPS, Gupta AC, Kumar R, Sethi S dan Singh S. Comparative Study Between Standard Dynamic Hip Screw (DHS) and Cemented Bipolar Arthroplasty in Trochanteric Fracture of Femur in Elderly Patients. Pb Journal of Orthopaedics 2012. XIII (1): 40-3.
- Pachore JA, Shah VI, Sheth AN, Kalpesh PS, Marothi DP dan Puri R. Hip Arthroplasty in Failed Intertrochanteric Fractures in Elderly. Indian J Orthop 2013. 47 (6): 572-7.
- Russell TA. Intertrochanteric Fracture. In: Bucholz RW, Heckman JD, Court-brown CM, Tornetta P [eds.]. Rockwood and Green's Fracture In Adults 7th ed. Philadelphia: Lippincott Williams & Wilkins; 2010: 1598-641.
- Hassankhani EG, Kashani FO, Hajitaghi H, dan Hassankhani GG. How to treat the Complex Unstable Intertrochanteric Fractures in Elderly Patients? DHS or Arthroplasty. Arch Bone Jt Surg 2014. 2(3):174-1.
- Zhang YHN, Lim CT, Shen L, Kevin L, dan Shamal DD. Clinical Outcome Following Treatment of Stable and Unstable Intertrochanteric fractures with Dynamic Hip Screw. Ann Acad Med Singapore 2011. 40: 482-7.
- Sinno K, Sakr M, Girard J, dan Khatib H. The Effectiveness of Primary Bipolar Arthroplasty in Treatment of Unstable Intertrochanteric fractures in elderly Patients. N Am J Med Sci 2010. 2 (12): 561-8.
- Hughes PE, Hsu JC, and Matave MJ. Hip Anatomy and Biomechanics in the Athlete. Sports Medicine and Arthroscopy Review. 2002; 10: 103-114.